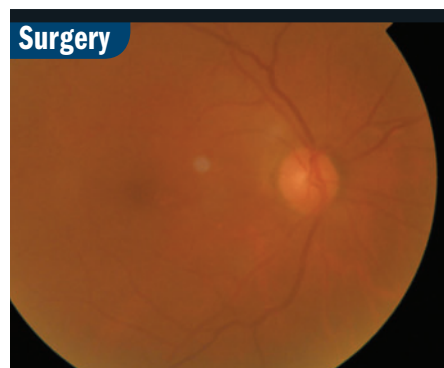


► OphthalmologyTimes.com



## VALUING MACULAR OCT FOR PREOP CATARACT SURGERY EVALUATION

**THOUGH THE DILATED** clinical fundus examination is considered the standard of care for preoperative evaluation of the macula, its limited ability to detect pathology in patients with opaque media is a specific concern in the setting of patients presenting for cataract surgery, explains Yishay Weill, MD.

“Preoperative OCT allows better patient management in terms of guiding appropriate surgery planning, timing, and planning, modification of consent, patient counseling, and matching patient expectations,” Dr. Weill said.

*Continues on page 10 : Macular OCT*

### Clinical Diagnosis

## EXPLORING NOCTURNAL EVAPORATIVE STRESS IN DRY EYE PATIENTS

**OPHTHALMOLOGISTS** frequently educate their patients on the role of sleep as a facilitator of overall good health. But, what happens when diligent sleepers wake with dry eye symptoms that are decidedly worse, not better?

The strange phenomena of her patients getting more and better sleep—and still waking up with peak severity dry eye symptoms—led Laura M. Periman, MD, to investigate the cause of, and potential remedies for, symptomatic dry eye that worsens overnight. Nocturnal evaporative stress is a frequently overlooked and undermanaged component of dry eye care. Dr. Periman shares some tips for a more proactive approach to identifying and managing these cases.

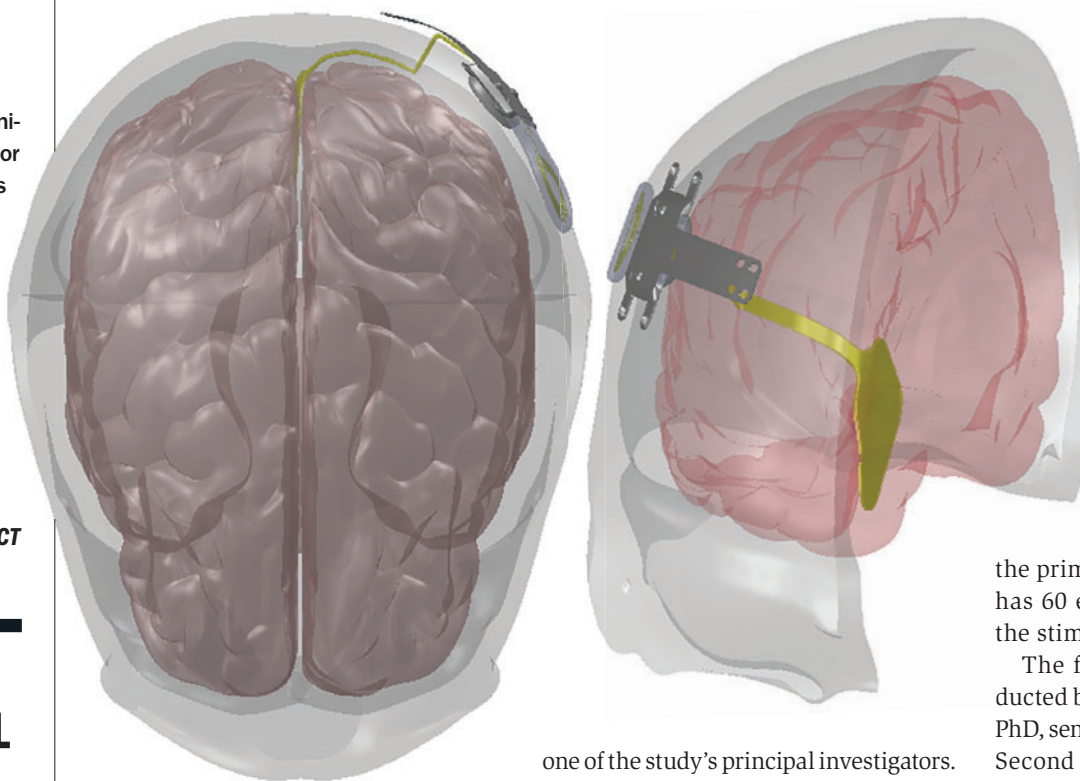
*Continues on page 36 : Nocturnal*



**HOSPITAL CLOSURES HURT** Impact far-reaching for patients, residency training slots for future ophthalmologists

# Device renews hope for artificial vision

## Visual cortical prosthesis intended to create artificial form of useful vision for blind individuals



### In View

► **THE VISUAL CORTICAL PROSTHESIS SYSTEM** is designed to bypass diseased or injured eye anatomy and to transmit these electrical pulses wirelessly to an array of electrodes implanted on the surface of the brain's visual cortex, where it is intended to provide the perception of patterns of light.

(Images courtesy of Second Sight Medical Products Inc.)

the primary visual cortex. The system has 60 electrical contacts that deliver the stimulation to the brain, he noted.

The feasibility study is being conducted by Dr. Pouratian; Jessy D. Dorn, PhD, senior director of scientific research, Second Sight Medical Products; Robert Greenberg, MD, PhD, at UCLA, and at Baylor College of Medicine, Houston, where Daniel Yoshor, MD, is site director and also one of the principal investigators.

Six subjects (five men, 1 woman; age range, 29-57 years), who became blind from disease or injury and had a normal visual cortex, participated and will be followed for 5 years. Specifically, three patients suffered a trauma, two had glaucoma, and one had endophthalmitis. To now, the average time after implantation is about 12 months.

During the first testing of the device after implantation, 2 weeks postoperatively, each electrical contact is turned on individually to determine at what level of stimulation results in a visual perception, i.e., phosphenes.

*Continues on page 13 : Cortical prosthesis*

one of the study's principal investigators.

“We need to realize that the goal of a system, such as [this], is not to restore vision as we know it in sighted individuals, but to restore visual perception to blind people to allow better function in and interaction with the world,” said Dr. Pouratian, associate professor of neurosurgery, Ronald Reagan UCLA Medical Center, Santa Monica, CA. “In achieving that goal, we are making huge progress.”

The visual cortical prosthesis system is designed to bypass the eyes and optic nerve, i.e., the diseased or injured tissue.

Patients wear a miniature camera mounted on a pair of eyeglasses, an antenna, and a video processing unit (VPU). The camera captures real-time images as processed by the VPU and then converted into stimulation patterns that are transmitted wirelessly to an electrode array implanted on the surface of


*By Lynda Charters; Reviewed by Nader Pouratian, MD, PhD*

**A NOVEL** visual cortical prosthesis system (Orion, Second Sight Medical Products) is expanding the pool of patients who can benefit from artificial vision.

Patients include not only those with retinal disease—such as retinitis pigmentosa, diabetic retinopathy, and glaucoma—but also those who have lost vision to eye injury or optic nerve injury/disease and are ineligible for any other visual prosthetic.

The FDA recently approved the system for an Early Feasibility Study through its Breakthrough Device pathway—and the latest results at 12 months have been positive, said Nader Pouratian, MD, PhD,

# Less stress, pure success ...in your O.R. day<sup>1</sup>



TM



**References:** 1. Omeros survey data on file. 2. Silverstein SM, Rana V, Stephens R, Segars L, Pankratz J, Shivani R, et al. Effect of phenylephrine 1.0%-ketorolac 0.3% injection on tamsulosin-associated intraoperative floppy-iris syndrome. *J Cataract Refract Surg.* 2018;44(9):1103-1108. 3. Rosenberg ED, Nattis AS, Alevi D, et al. Visual outcomes, efficacy, and surgical complications associated with intracameral phenylephrine 1.0%/ketorolac 0.3% administered during cataract surgery. *Clin Ophthalmol.* 2018;12:21-28. 4. Bucci FA Jr, Michalek B, Fluet AT. Comparison of the frequency of use of a pupil expansion device with and without an intracameral phenylephrine and ketorolac injection 1%/0.3% at the time of routine cataract surgery. *Clin Ophthalmol.* 2017;11:1039-1043. 5. Visco D. Effect of phenylephrine/ketorolac on iris fixation ring use and surgical times in patients at risk of intraoperative miosis. *Clin Ophthalmol.* 2018;12:301-305. 6. Walter K, Delwadia N. Miosis prevention in femtosecond cataract surgery using a continuous infusion of phenylephrine and ketorolac. Presented at: 2018 American Society of Cataract and Refractive Surgery (ASCRS) and American Society of Ophthalmic Administrators (ASOA) Annual Meeting; April 13-17, 2018; Washington, DC. 7. Matossian C. Clinical outcomes of phenylephrine/ketorolac vs. epinephrine in cataract surgery in a real-world setting. Presented at: American Society of Cataract and Refractive Surgery (ASCRS) and American Society of Ophthalmic Administrators (ASOA) Annual Meeting; April 13-17, 2018; Washington, DC. 8. Al-Hashimi S, Donaldson K, Davidson R, et al. Medical and surgical management of the small pupil during cataract surgery. *J Cataract Refract Surg.* 2018;44:1032-1041. 9. Gayton JL. E-poster presented at: 15th International Congress on Vision Science and Eye; 2017 Aug 10-11; London, UK. 10. Katsev DA, Katsev CC, Pinnow J, Lockhart CM. Intracameral ketorolac concentration at the beginning and end of cataract surgery following preoperative topical ketorolac administration. *Clin Ophthalmol.* 2017;11:1897-1901. 11. Waterbury LD. Alternative drug delivery for patients undergoing cataract surgery as demonstrated in a canine model. *J Ocul Pharmacol Ther.* 2018;34:154-160. 12. Visco D, et al. Study to evaluate patient outcomes following cataract surgery when using Omidria with postoperative topical NSAID administration versus a standard regimen of postoperative topical NSAIDs and steroids. Presented at: 28th Annual Meeting of the American College of Eye Surgeons (ACES), the American Board of Eye Surgery (ABES), and the Society for Excellence in Eyecare (SEE), Caribbean Eye Meeting; February 1-5, 2019; Cancún, Mexico. 13. Omidria [package insert]. Seattle, WA: Omeros Corporation; 2017.

OMIDRIA® (phenylephrine and ketorolac intraocular solution) 1% / 0.3% is added to ophthalmic irrigating solution used during cataract surgery or intraocular lens replacement and is indicated for maintaining pupil size by preventing intraoperative miosis and reducing postoperative ocular pain.

## The data are compelling and consistent—OMIDRIA makes cataract surgery better for you and your patients

Published and presented clinical studies and manuscripts in press and/or in preparation report that in post-launch (i.e., not included in current labeling), prospective and retrospective, double-masked and open-label, cohort and case-controlled, single- and multi-center analyses, the use of OMIDRIA, compared to the surgeons' standard of care, statistically significantly:

- Prevents Intraoperative Floppy Iris Syndrome (IFIS)<sup>2</sup>
- Reduces complication rates (epinephrine comparator)<sup>3</sup>
- Decreases use of pupil-expanding devices (epinephrine comparator)<sup>3-8</sup>
- Reduces surgical times (epinephrine comparator)<sup>3,5,7,8</sup>
- Prevents miosis during femtosecond laser-assisted surgery (epinephrine comparator)<sup>6,9</sup>
- Improves uncorrected visual acuity on day after surgery (epinephrine comparator)<sup>3</sup>
- Delivers NSAID to the anterior chamber and related structures better than routine preoperative topical drug administration, resulting in effectively complete postoperative inhibition of COX-1 and COX-2<sup>10,11</sup>
- Reduces the incidence of rebound iritis, postoperative pain/photophobia, and cystoid macular edema (CME) in patients without preoperative vitreomacular traction (VMT), when used with a postoperative topical NSAID (compared to postoperative topical NSAID + corticosteroid without OMIDRIA)<sup>12</sup>

## OMIDRIA inhibits prostaglandin release, reducing intraoperative inflammation, to prevent miosis and reduce postoperative pain<sup>13</sup>

**OMIDRIA is separately reimbursed under Medicare Part B and by many Medicare Advantage and commercial payers.\***

**Contact your OMIDRIA representative today or visit [omidria.com](http://omidria.com) to learn more.**

\*Based on currently available information and subject to change without notice. Individual plan coverage, policies, and procedures may vary and should be confirmed. Omeros does not guarantee coverage or payment.

### IMPORTANT SAFETY INFORMATION

OMIDRIA must be added to irrigating solution prior to intraocular use.

OMIDRIA is contraindicated in patients with a known hypersensitivity to any of its ingredients.

Systemic exposure of phenylephrine may cause elevations in blood pressure.

Use OMIDRIA with caution in individuals who have previously exhibited sensitivities to acetylsalicylic acid, phenylacetic acid derivatives, and other nonsteroidal anti-inflammatory drugs (NSAIDs), or have a past medical history of asthma.

The most commonly reported adverse reactions at  $\geq 2\%$  are eye irritation, posterior capsule opacification, increased intraocular pressure, and anterior chamber inflammation.

**Please see the Full Prescribing Information for OMIDRIA at [www.omidria.com/prescribinginformation](http://www.omidria.com/prescribinginformation).**

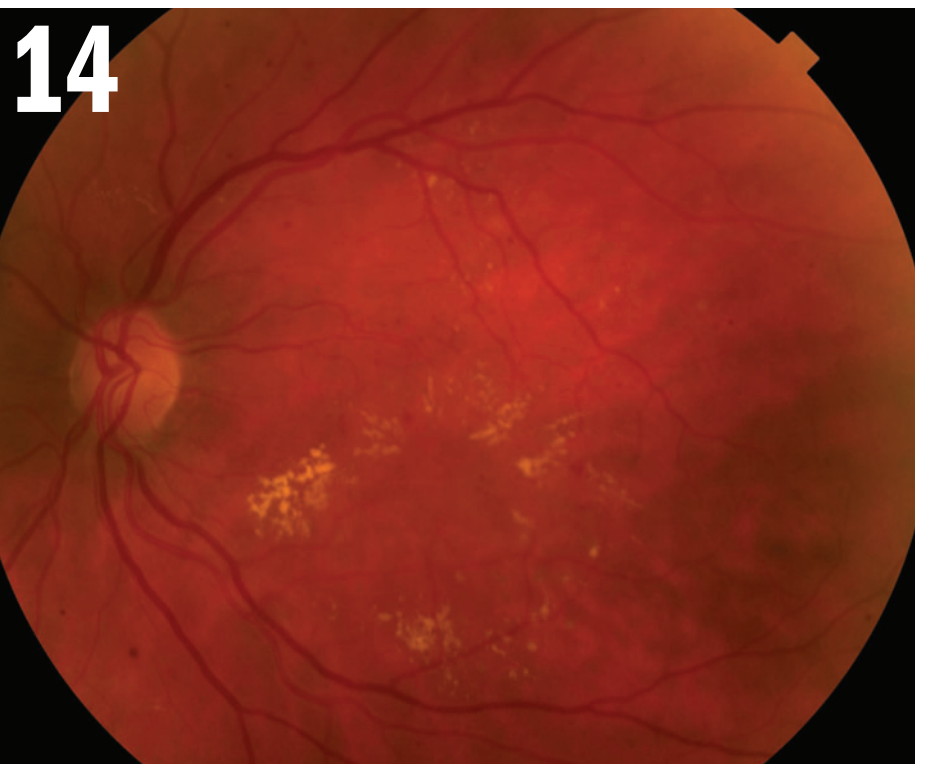
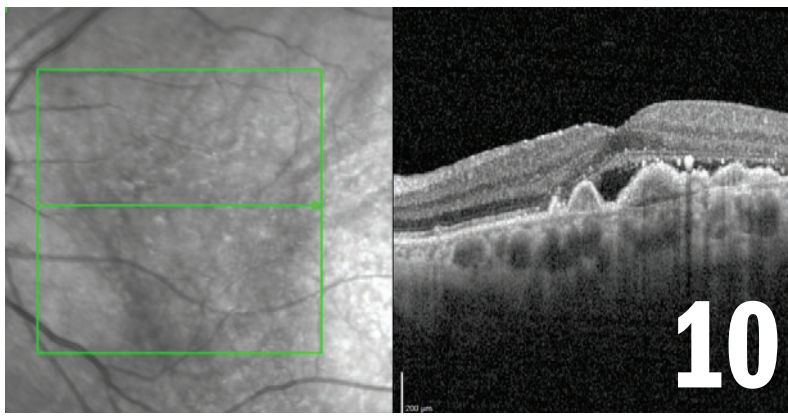
**You are encouraged to report Suspected Adverse Reactions to the FDA. Visit [www.fda.gov/medwatch](http://www.fda.gov/medwatch), or call 1-800-FDA-1088.**

OMIDRIA® and the OMIDRIA logo® are registered trademarks of Omeros Corporation.  
© Omeros Corporation 2019, all rights reserved. 2019-005



**OMIDRIA®**

(phenylephrine and ketorolac  
intraocular solution)  
1% / 0.3%



## Surgery

### 18 CONSIDER HYPOTONY SYMPTOMS DURING THERAPY

Though numerous techniques are available to surgeons, awareness is important.

## Drug Therapy

### 33 STUDY LINKS LONG-TERM STATIN USE WITH LOWER POAG RISK

Patients who used statins for five years or more had reduced chance of glaucoma.

## Clinical Diagnosis

### 36 EXPLORING DRY EYE SYMPTOMS THAT WORSEN DURING NIGHT

Poor eyelid performance while sleeping may be common contributing factor.

*In This Issue*    6 EDITORIAL    34 MARKETPLACE

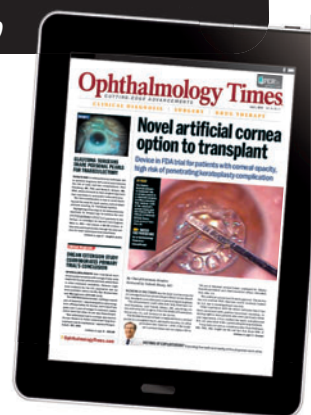## What's Trending

See what the ophthalmic community is reading on *OphthalmologyTimes.com*

- 1 PODCAST: Here's why IPL is a practice game changer**  
<http://bit.ly/2JOjrsG>
- 2 Investigate NES in dry eye patients**  
<http://bit.ly/2LfVb5A>
- 3 Physician burnout: Truth or myth?**  
<http://bit.ly/2XY3TaT>
- 4 OCT and OCTA: Seeing deeper into sickle cell retinopathy**  
<http://bit.ly/2xTKqOd>

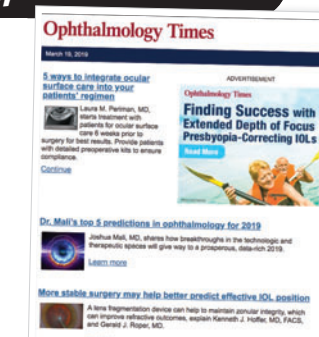## Digital App

Introducing the *Ophthalmology Times* app for iPad and iPhone. Download it for free today at [OphthalmologyTimes.com/OTapp](http://OphthalmologyTimes.com/OTapp).

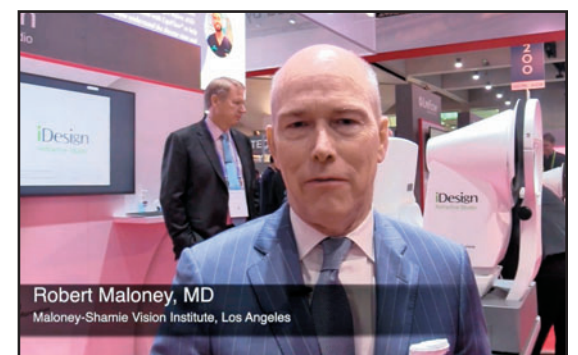

## eNewsletter

Sign up for *Ophthalmology Times'* weekly newsletter at <https://bit.ly/20qBJ56>.



## Video



Robert Maloney, MD  
Maloney-Shamie Vision Institute, Los Angeles

Robert Maloney, MD, discusses how a novel system can better assist refractive surgeons. Go to <http://bit.ly/2Gk4fIU>

## Facebook

Like *Ophthalmology Times* at [Facebook.com/OphthalmologyTimes](https://www.facebook.com/OphthalmologyTimes)

# THE RIGHT ROUTE CAN MAKE ALL THE DIFFERENCE



**Access retinal disease directly  
through the suprachoroidal space.**

The suprachoroidal space provides a novel approach to drug delivery, offering new opportunities to access diseased tissue in the back of the eye.<sup>1</sup>

▶ See the potential at [SuprachoroidalSpace.com](https://SuprachoroidalSpace.com)

**Reference: 1.** Chiang B, Jung JH, Prausnitz MR. The suprachoroidal space as a route of administration to the posterior segment of the eye. *Adv Drug Deliv Rev.* 2018;126:58-66.

MMM-0038 02/19 © 2019 Clearside Biomedical, Inc.

# Hospital closures hurt

Impact far-reaching from patients to residency training



By **Peter J. McDonnell, MD**

director of the Wilmer Eye Institute, Johns Hopkins University School of Medicine, Baltimore, and chief medical editor of *Ophthalmology Times*.

He can be reached at 727 Maumenee Building 600 N. Wolfe St. Baltimore, MD 21287-9278  
Phone: 443/287-1511 Fax: 443/287-1514  
E-mail: pmcdonn1@jhmi.edu

**THE MORNING** newspaper reports the bankruptcy of a large inner-city hospital in Philadelphia. Hahnemann Hospital—which has 496 beds and treats 56,000 patients a year in its emergency room—announced it had liabilities in the range of \$100-\$500 million and assets in the range of \$10-\$50 million (in other words, it is a financial disaster).

News reports state that the hospital has stopped accepting trauma patients despite statements from government regulators that this was not acceptable.

One report says the state has issued an order for the hospital to “cease and desist” its closure plans. Along with court battles is the weighing in of one presidential candidate, Sen. Bernie Sanders (D-VT), who calls closure of the hospital “insane.”

While I have no information about this confused state of events beyond that published in the media, my belief is that events like this are likely to occur from time to time—possibly with increasing frequency—in coming years.

Many academic medical centers located within inner cities are meeting important healthcare needs of a community in which poor nutrition, obesity, drug use, limited education, chronic medical illnesses, and poverty are becoming increasingly common.

As regulatory requirements (think electronic medical records, compliance programs, etc.) and increasing costs overall drive up expenses, our society is increasingly unwilling to write larger and larger checks to cover the costs for those who are uninsured or underinsured.

## CHANGING TIMES

I suppose fans of Darwin would say that this type of process is necessary to winnow out those institutions that cannot adapt to the changing realities of our healthcare system.

Increasingly, for teaching hospitals in urban areas, the game is to provide excellent high-level care for complicated problems in order to attract

complicated patients with good insurance who will travel to access this high-quality care.

Payments received for the care of these complicated patients can then be used to subsidize the care provided to local patients with “bread-and-butter” medical issues and whose insurance does not come close to covering the cost of care (Medicaid) or who have no insurance at all and lack the means to pay.

My reference to teaching in the paragraph above highlights one bit of collateral damage in this drama—the ophthalmology residency program in this hospital is being shut down.

Though I don’t know a great deal about this particular residency program, it is clear that inner-city hospitals provide fertile ground for residents eager to learn by helping patients.

Preventing or reducing vision loss from diabetic retinopathy and glaucoma—two common diseases that disproportionately impact these communities—allow residents to have a positive impact.

The ocular trauma that is unfortunately too common in our large cities provide residents an important experience. And few things are more delightful to an ophthalmologist-in-training than restoring the sight of a person with a severe cataract who cannot afford to pay anything.

It will be stressful for the ophthalmology residents (as well as those in other specialties) if they must relocate to different programs in different cities, but in the past such residents have been assured of the ability to complete their training.


It is not good for our profession or the American public, however, if the number of training slots in ophthalmology is allowed to decrease.

With the continued growth in the U.S. population, combined with the demographic tidal wave of senior citizens, this is not a good time for us to reduce the number of future ophthalmologists. ■

## REFERENCE

- <https://philadelphia.cbslocal.com/2019/07/14/presidential-candidate-bernie-sanders-hahnemann-university-hospital-closure/>

## THE CYCLE OF INFLAMMATION IN DRY EYE DISEASE<sup>2</sup>




Ocular Surface Stress



Inflammation



Tear Film Instability



Signs & Symptoms



# XIIDRA MAY INTERRUPT THE CYCLE OF INFLAMMATION CENTRAL TO DRY EYE DISEASE<sup>1,2</sup>

The exact mechanism of action of Xiidra in Dry Eye Disease is not known.<sup>1</sup>

**Xiidra blocks the interaction of ICAM-1 and LFA-1, which is a key mediator of the inflammation central to Dry Eye Disease. *In vitro* studies have shown that Xiidra may inhibit the recruitment of previously activated T cells, the activation of newly recruited T cells, and the release of pro-inflammatory cytokines.<sup>1</sup>**

.....  
**Check out Xiidra-ECP.com**  
.....

#### Indication

Xiidra® (lifitegrast ophthalmic solution) 5% is indicated for the treatment of signs and symptoms of dry eye disease (DED).

#### Important Safety Information

Xiidra is contraindicated in patients with known hypersensitivity to lifitegrast or to any of the other ingredients.

In clinical trials, the most common adverse reactions reported in 5-25% of patients were instillation site irritation, dysgeusia and reduced visual acuity. Other adverse reactions reported in 1% to 5% of the patients were blurred vision, conjunctival hyperemia, eye irritation, headache, increased lacrimation, eye discharge, eye discomfort, eye pruritus and sinusitis.

To avoid the potential for eye injury or contamination of the solution, patients should not touch the tip of the single-use container to their eye or to any surface.

Contact lenses should be removed prior to the administration of Xiidra and may be reinserted 15 minutes following administration.

Safety and efficacy in pediatric patients below the age of 17 years have not been established.

For additional safety information, see accompanying Brief Summary of Safety Information on the adjacent page and Full Prescribing Information on Xiidra-ECP.com.

#### References:

1. Xiidra [Prescribing Information]. Lexington, MA: Shire US. 2. TFOS DEWS II Research Subcommittee. Report of the Research Subcommittee of the Tear Film & Ocular Surface Society Dry Eye WorkShop II (2017). *Ocul Surf.* 2017;15(3):269-275.



## BRIEF SUMMARY:

Consult the Full Prescribing Information for complete product information.

## INDICATIONS AND USAGE

Xiidra® (lifitegrast ophthalmic solution) 5% is indicated for the treatment of the signs and symptoms of dry eye disease (DED).

## DOSAGE AND ADMINISTRATION

Instill one drop of Xiidra twice daily (approximately 12 hours apart) into each eye using a single-use container. Discard the single-use container immediately after using in each eye. Contact lenses should be removed prior to the administration of Xiidra and may be reinserted 15 minutes following administration.

## CONTRAINDICATIONS

Xiidra is contraindicated in patients with known hypersensitivity to lifitegrast or to any of the other ingredients in the formulation.

## ADVERSE REACTIONS

### Clinical Trials Experience

Because clinical studies are conducted under widely varying conditions, adverse reaction rates observed in clinical studies of a drug cannot be directly compared to rates in the clinical trials of another drug and may not reflect the rates observed in practice. In five clinical studies of dry eye disease conducted with lifitegrast ophthalmic solution, 1401 patients received at least 1 dose of lifitegrast (1287 of which received lifitegrast 5%). The majority of patients (84%) had  $\leq 3$  months of treatment exposure. 170 patients were exposed to lifitegrast for approximately 12 months. The majority of the treated patients were female (77%). The most common adverse reactions reported in 5-25 % of patients were instillation site irritation, dysgeusia and reduced visual acuity. Other adverse reactions reported in 1% to 5% of the patients were blurred vision, conjunctival hyperemia, eye irritation, headache, increased lacrimation, eye discharge, eye discomfort, eye pruritus and sinusitis.

### Postmarketing Experience

The following adverse reactions have been identified during postapproval use of Xiidra. Because these reactions are reported voluntarily from a population of uncertain size, it is not always possible to reliably estimate their frequency or establish a causal relationship to drug exposure.

Rare cases of hypersensitivity, including anaphylactic reaction, bronchospasm, respiratory distress, pharyngeal edema, swollen tongue, and urticaria have been reported. Eye swelling and rash have been reported.

## USE IN SPECIFIC POPULATIONS

### Pregnancy

There are no available data on Xiidra use in pregnant women to inform any drug associated risks. Intravenous (IV) administration of lifitegrast to pregnant rats, from pre-mating through gestation day 17, did not produce teratogenicity at clinically relevant systemic exposures. Intravenous administration of lifitegrast to pregnant rabbits during organogenesis produced an increased incidence of omphalocele at the lowest dose

tested, 3 mg/kg/day (400-fold the human plasma exposure at the recommended human ophthalmic dose [RHOD], based on the area under the curve [AUC] level). Since human systemic exposure to lifitegrast following ocular administration of Xiidra at the RHOD is low, the applicability of animal findings to the risk of Xiidra use in humans during pregnancy is unclear.

## Animal Data

Lifitegrast administered daily by intravenous (IV) injection to rats, from pre-mating through gestation day 17, caused an increase in mean preimplantation loss and an increased incidence of several minor skeletal anomalies at 30 mg/kg/day, representing 5,400-fold the human plasma exposure at the RHOD of Xiidra, based on AUC. No teratogenicity was observed in the rat at 10 mg/kg/day (460-fold the human plasma exposure at the RHOD, based on AUC). In the rabbit, an increased incidence of omphalocele was observed at the lowest dose tested, 3 mg/kg/day (400-fold the human plasma exposure at the RHOD, based on AUC), when administered by IV injection daily from gestation days 7 through 19. A fetal No Observed Adverse Effect Level (NOAEL) was not identified in the rabbit.

## Lactation

There are no data on the presence of lifitegrast in human milk, the effects on the breastfed infant, or the effects on milk production. However, systemic exposure to lifitegrast from ocular administration is low. The developmental and health benefits of breastfeeding should be considered, along with the mother's clinical need for Xiidra and any potential adverse effects on the breastfed child from Xiidra.

## Pediatric Use

Safety and efficacy in pediatric patients below the age of 17 years have not been established.

## Geriatric Use

No overall differences in safety or effectiveness have been observed between elderly and younger adult patients.

## NONCLINICAL TOXICOLOGY

### Carcinogenesis, Mutagenesis, Impairment of Fertility

*Carcinogenesis:* Animal studies have not been conducted to determine the carcinogenic potential of lifitegrast.

*Mutagenesis:* Lifitegrast was not mutagenic in the *in vitro* Ames assay. Lifitegrast was not clastogenic in the *in vivo* mouse micronucleus assay. In an *in vitro* chromosomal aberration assay using mammalian cells (Chinese hamster ovary cells), lifitegrast was positive at the highest concentration tested, without metabolic activation.

*Impairment of fertility:* Lifitegrast administered at intravenous (IV) doses of up to 30 mg/kg/day (5400-fold the human plasma exposure at the recommended human ophthalmic dose (RHOD) of lifitegrast ophthalmic solution, 5%) had no effect on fertility and reproductive performance in male and female treated rats.



Manufactured for: Shire US Inc., 300 Shire Way, Lexington, MA 02421. For more information, go to [www.Xiidra.com](http://www.Xiidra.com) or call 1-800-828-2088. Marks designated ® and ™ are owned by Shire or an affiliated company. ©2018 Shire US Inc. SHIRE and the Shire Logo are trademarks or registered trademarks of Shire Pharmaceutical Holdings Ireland Limited or its affiliates.

Patented: please see <https://www.shire.com/legal-notice/product-patents>  
Last Modified: 01/2018 S33769





# Macular OCT assists preop cataract surgery evaluation

Study shows routine use may improve patient management, guide procedure planning

By Cheryl Guttman Krader; Reviewed by Yishay Weill, MD

**R**esults of a retrospective study support the routine use of macular optical coherence tomography (OCT) for preoperative screening of patients scheduled for cataract surgery, according to Yishay Weill, MD.

The research evaluated data from 226 consecutive eyes of 226 patients referred to Shaare Zedek Medical Center, Jerusalem, Israel, for cataract surgery during the last two months of 2017. It found that the macular OCT was normal in 51% of eyes and uninterpretable due to low quality in 9%.

However, macular pathology was identified in 40% of the eyes. Importantly, the pathology was overlooked in the referral examination in 51% of the eyes with pathology, and its presence led to a change in management in 14% of patients.

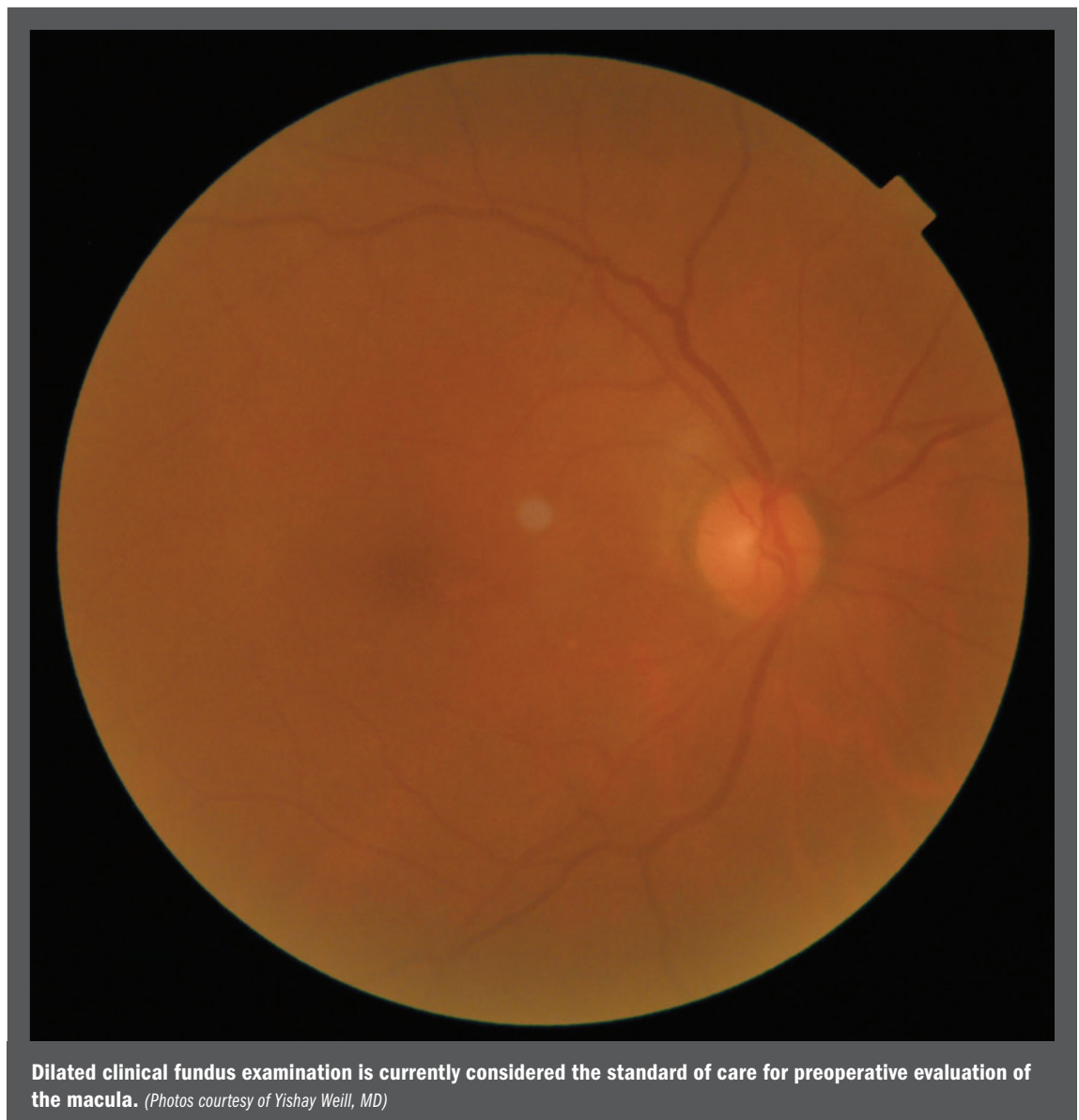“Cataract surgery is now a combined rehabilitative and refractive procedure, and our patients’ expectations are higher than ever,” said Dr. Weill, resident, Department of Ophthalmology, Shaare Zedek Medical Center.

Dr. Weill noted that the dilated clinical fundus



**‘Preoperative OCT allows better patient management in terms**

**of guiding appropriate surgery planning, timing, modification of consent, patient counseling, and matching patient expectations.’** — Yishay Weill, MD



Dilated clinical fundus examination is currently considered the standard of care for preoperative evaluation of the macula. (Photos courtesy of Yishay Weill, MD)

examination is currently considered the standard of care for preoperative evaluation of the macula.

“Its limited ability to detect pathology in patients with opaque media is a specific concern in the setting of patients presenting for cataract surgery,” he pointed out.

Dr. Weill also explained that overlooked macu-

lar pathologies might lead to suboptimal postoperative results, such as unexpected low BCVA and worsening of baseline macular pathology, and that will in turn could lead to dissatisfied patients.

“Preoperative OCT allows better patient management in terms of guiding appropriate surgery

*Continues on page 12 : OCT*

# Dextenza<sup>®</sup>

(dexamethasone ophthalmic insert) 0.4 mg  
for intracanalicular use

FDA APPROVED.  
C-CODE 9048 EFFECTIVE JULY 1.

# BIG TIME INNOVATION<sup>1</sup>

THE FIRST AND ONLY  
OPHTHALMIC STEROID INSERT

**DEXTENZA is an advancement in steroid treatment**

- Resorbable, so no need for removal<sup>2</sup>
- Insert can be removed via saline irrigation or manual expression, if necessary<sup>2</sup>
- Physicians rated DEXTENZA as easy to insert<sup>3\*</sup>
- Designed to deliver a tapered dose<sup>1</sup>
- Contains fluorescein for visualization<sup>2</sup>
- No additional components or assembly required<sup>2</sup>

**LEARN MORE AT DEXTENZA.COM**

## INDICATION

DEXTENZA is a corticosteroid indicated for the treatment of ocular pain following ophthalmic surgery.

## IMPORTANT SAFETY INFORMATION

### CONTRAINDICATIONS

DEXTENZA is contraindicated in patients with active corneal, conjunctival or canalicular infections, including epithelial herpes simplex keratitis (dendritic keratitis), vaccinia, varicella; mycobacterial infections; fungal diseases of the eye, and dacryocystitis.

### WARNINGS AND PRECAUTIONS

Prolonged use of corticosteroids may result in glaucoma with damage to the optic nerve, defects in visual acuity and fields of vision. Steroids should be used with caution in the presence of glaucoma. Intraocular pressure should be monitored during treatment.

Corticosteroids may suppress the host response and thus increase the hazard for secondary ocular infections. In acute purulent conditions, steroids may mask infection and enhance existing infection.

Use of ocular steroids may prolong the course and may exacerbate the severity of many viral infections of the eye (including herpes simplex).

Fungus invasion must be considered in any persistent corneal ulceration where a steroid has been used or is in use. Fungal culture should be taken when appropriate.

Use of steroids after cataract surgery may delay healing and increase the incidence of bleb formation.

### ADVERSE REACTIONS

The most common ocular adverse reactions that occurred in patients treated with DEXTENZA were: anterior chamber inflammation including iritis and iridocyclitis (9%); intraocular pressure increased (5%); visual acuity reduced (2%); eye pain (1%); cystoid macular edema (1%); corneal edema (1%); and conjunctival hyperemia (1%).

The most common non-ocular adverse reaction that occurred in patients treated with DEXTENZA was headache (1%).

**Please see brief summary of full Prescribing Information on adjacent page.**

\*73.6% of physicians in Study 1 and 76.4% in Study 2 rated DEXTENZA as easy to insert.

**References:** **1.** Sawhney AS et al, inventors; Incept LLC, assignee. US patent 8,409,606 B2. April 2, 2013. **2.** DEXTENZA [package insert]. Bedford, MA: Ocular Therapeutix, Inc; 2018. **3.** Walters T et al. *J Clin Exp Ophthalmol.* 2016;7(4):1-11.

© 2019 Ocular Therapeutix, Inc. All rights reserved.  
DEXTENZA is a registered trademark of Ocular Therapeutix, Inc. PP-US-DX-0071 02/2019

**Ocular**  
Therapeutix™

# Dextenza®

(dexamethasone ophthalmic insert) 0.4mg  
for intracanalicular use

**BRIEF SUMMARY:** Please see the DEXTENZA Package Insert for full prescribing information for DEXTENZA (11/2018)

## 1 INDICATIONS AND USAGE

DEXTENZA® (dexamethasone ophthalmic insert) is a corticosteroid indicated for the treatment of ocular pain following ophthalmic surgery (1).

## 4 CONTRAINDICATIONS

DEXTENZA is contraindicated in patients with active corneal, conjunctival or canalicular infections, including epithelial herpes simplex keratitis (dendritic keratitis), vaccinia, varicella; mycobacterial infections; fungal diseases of the eye, and dacryocystitis.

## 5 WARNINGS AND PRECAUTIONS

### 5.1 Intraocular Pressure Increase

Prolonged use of corticosteroids may result in glaucoma with damage to the optic nerve, defects in visual acuity and fields of vision. Steroids should be used with caution in the presence of glaucoma. Intraocular pressure should be monitored during the course of the treatment.

### 5.2 Bacterial Infection

Corticosteroids may suppress the host response and thus increase the hazard for secondary ocular infections. In acute purulent conditions, steroids may mask infection and enhance existing infection [see Contraindications (4)].

### 5.3 Viral Infections

Use of ocular steroids may prolong the course and may exacerbate the severity of many viral infections of the eye (including herpes simplex) [see Contraindications (4)].

### 5.4 Fungal Infections

Fungus invasion must be considered in any persistent corneal ulceration where a steroid has been used or is in use. Fungal culture should be taken when appropriate [see Contraindications (4)].

### 5.5 Delayed Healing

The use of steroids after cataract surgery may delay healing and increase the incidence of bleb formation.

## 6 ADVERSE REACTIONS

The following serious adverse reactions are described elsewhere in the labeling:

- Intraocular Pressure Increase [see Warnings and Precautions (5.1)]
- Bacterial Infection [see Warnings and Precautions (5.2)]
- Viral Infection [see Warnings and Precautions (5.3)]
- Fungal Infection [see Warnings and Precautions (5.4)]
- Delayed Healing [see Warnings and Precautions (5.5)]

### 6.1 Clinical Trials Experience

Because clinical trials are conducted under widely varying conditions, adverse reaction rates observed in the clinical trials of a drug cannot be directly compared to rates in the clinical trials of another drug and may not reflect the rates observed in practice. Adverse reactions associated with ophthalmic steroids include elevated intraocular pressure, which may be associated with optic nerve damage, visual acuity and field defects, posterior subcapsular cataract formation; delayed wound healing; secondary ocular infection from pathogens including herpes simplex, and perforation of the globe where there is thinning of the cornea or sclera [see Warnings and Precautions (5)].

DEXTENZA was studied in three randomized, vehicle-controlled studies (n = 351). The mean age of the population was 68 years (range 43 to 87 years), 62% were female, and 85% were white. Forty-six percent had brown iris color and 31% had blue iris color. The most common ocular adverse reactions that occurred in patients treated with DEXTENZA were: anterior chamber inflammation including iritis and iridocyclitis (9%); intraocular pressure increased (5%); visual acuity reduced (2%); eye pain (1%); cystoid macular edema (1%); corneal edema (1%); and conjunctival hyperemia (1%).

The most common non-ocular adverse reaction that occurred in patients treated with DEXTENZA was headache (1%).

## 8 USE IN SPECIFIC POPULATIONS

### 8.1 Pregnancy

#### Risk Summary

There are no adequate or well-controlled studies with DEXTENZA in pregnant women to inform a drug-associated risk for major birth defects and miscarriage. In animal reproduction studies, administration of topical ocular dexamethasone to pregnant mice and rabbits during organogenesis produced embryofetal lethality, cleft palate and multiple visceral malformations [see Animal Data].

#### Data

##### Animal Data

Topical ocular administration of 0.15% dexamethasone (0.75 mg/kg/day) on gestational days 10 to 13 produced embryofetal lethality and a high incidence of cleft palate in a mouse study. A daily dose of 0.75 mg/kg/day in the mouse is approximately 5 times the entire dose of dexamethasone in the DEXTENZA product, on a mg/m<sup>2</sup> basis. In a rabbit study, topical ocular administration of 0.1% dexamethasone throughout organogenesis (0.36 mg/day, on gestational day 6 followed by 0.24 mg/day on gestational days 7-18) produced intestinal anomalies, intestinal aplasia, gastroschisis and hypoplastic kidneys. A daily dose of 0.24 mg/day is approximately 6 times the entire dose of dexamethasone in the DEXTENZA product, on a mg/m<sup>2</sup> basis.

### 8.2 Lactation

Systemically administered corticosteroids appear in human milk and could suppress growth and interfere with endogenous corticosteroid production; however the systemic concentration of dexamethasone following administration of DEXTENZA is low [see Clinical Pharmacology (12.3)]. There is no information regarding the presence of DEXTENZA in human milk, the effects of the drug on the breastfed infant or the effects of the drug on milk production to inform risk of DEXTENZA to an infant during lactation. The developmental and health benefits of breastfeeding should be considered along with the mother's clinical need for DEXTENZA and any potential adverse effects on the breastfed child from DEXTENZA.

### 8.4 Pediatric Use

Safety and effectiveness in pediatric patients have not been established.

### 8.5 Geriatric Use

No overall differences in safety or effectiveness have been observed between elderly and younger patients.

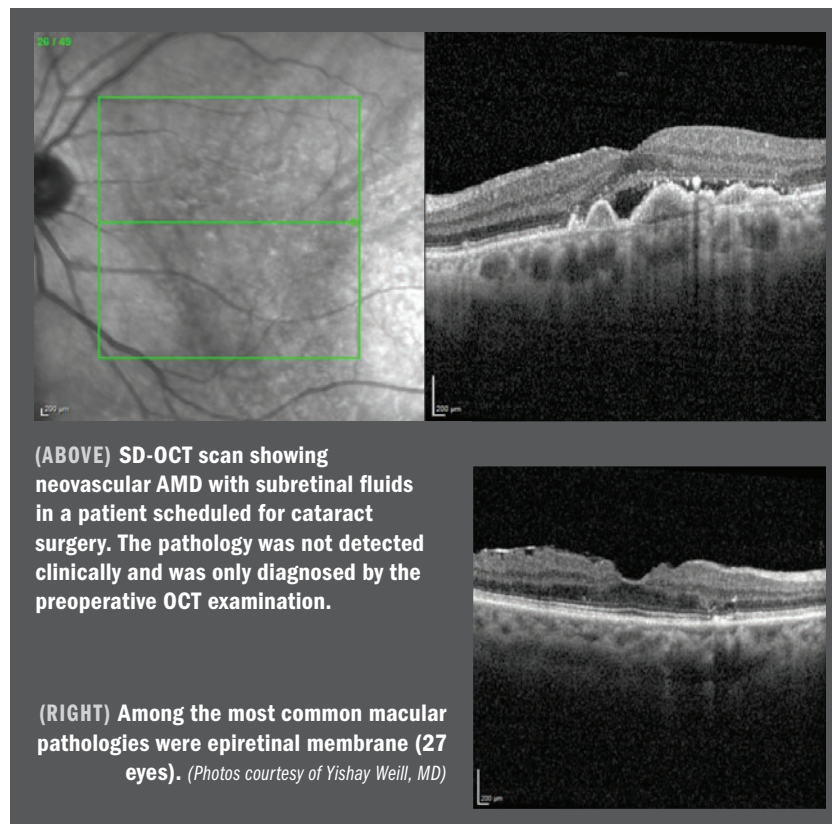
## 17 PATIENT COUNSELING INFORMATION

Advise patients to consult their surgeon if pain, redness, or itching develops.

**Ocular**  
Therapeutix™

**MANUFACTURED FOR:**  
Ocular Therapeutix, Inc.  
Bedford, MA 01730 USA  
PP-US-DX-0072

# surgery



## OCT

(Continued from page 10)

planning, timing, modification of consent, patient counseling, and matching patient expectations,” Dr. Weill said. “At our institution, a policy for routinely performing macular OCT for screening of cataract patients was implemented during the second half of 2017.”

The 226 patients included in the research study had a mean age of 73 years, were predominantly female (57%), and were seen by their referring eye care practitioner at an average of 59 days before their preoperative OCT.

The macular OCT was performed with a spectral-domain system (Spectralis, Heidelberg Engineering).

All of the OCT scans were then reviewed by a retina specialist.

Some of the patients found to have macular pathologies had more than one finding.

The most common macular pathologies were age-related macular de-

generation (43 eyes), epiretinal membranes (27 eyes), and cystoid macular edema (18 eyes).

“All patients found to have macular pathologies were disqualified as candidates for a multifocal IOL,” said Dr. Weill.

In some patients, discovering overlooked macular pathology using OCT led to a delay in surgery, and an offering

of combined surgery to address the macular pathology and cataract, or use of adjunctive therapy, such as an intravitreal injection of a corticosteroid or anti-VEGF agent.

Dr. Weill also pointed out that preoperative macular OCT is easy to implement because it is widely available, non-invasive, and quick.

However, he concluded that the need for research to evaluate the cost-effectiveness of its routine use for preoperative evaluation of cataract surgery patients. ■

## TAKE-HOME

► In a retrospective study, preoperative macular OCT identified macular pathology overlooked on fundus examination, and the findings led to management changes in a large percentage of patients.

**YISHAY WEILL, MD**

E: yishayweill@gmail.com

This article is adopted from a presentation by Dr. Weill at AAO2018. He has no relevant financial interests to disclose.

## CORTICAL PROSTHESIS

(Continued from page 1)

Following that initial testing session, patients continued to adapt to the device and were ready to take the device home for use after about 3 months.


Six months after implantation, the impact of the implant on patients' well-being and functional vision was evaluated. Of the five patients with formal evaluation at 6 months, two (40%) of the patients had a significant and three (60%) had a mild improvement in visual function.

"Every patient saw some visual perception in response to stimulation at almost every electrode when activated," Dr. Pouratian said. "Patients described phosphenes of different shapes that appeared as a spot of light, a circle, an oval, or a line."

### VISUAL REHABILITATION

Patients work with visual rehabilitation specialists once they begin to use the device at home.

"A major step is their learning how to use the device in a meaningful way," Dr. Pouratian said. "The visual perceptions of these patients who have bare or no light perception are not the same as those of sighted individuals, but we have found that the visual perceptions can be meaningful changes to them."



Dr. Pouratian

Some of the subjects can use the device to perform square localization, i.e., the ability to identify a square presented on a screen. When direction-of-motion testing was performed, many were able to identify accurately the direction of movement, he noted.

More significant than objective testing, however, is real-world use of the device.

For instance, one patient was able to locate a cue ball on a pool table. Another patient described cars that were parked on the side of the street and the direction in which other people on the sidewalk were moving and how the device allowed him to navigate better.

Investigators reported the occurrence of five adverse events in two patients, only one of which was serious (seizure).

### ACCELERATED DEVELOPMENT

With encouraging results from the first six subjects, the company is on a path to accelerated development of the visual cortical prosthesis system, explained Will McGuire, president and chief executive officer of Second Sight.

"With five subjects out to the 1-year mark, the company has increasing confidence in the clinical data," he said.

Because the visual cortical prosthesis system can treat more blind patients with different pathologies, the market has the potential to be up to 50 times larger than that with the company's retinal pros-

thesis system (Argus II), which treats only retinitis pigmentosa, according to McGuire.

Finally, the visual cortical prosthesis system is a more attractive platform, in that its technology and the visual quality and usefulness can be improved more compared with Argus, i.e., the potential use of more electrodes and, thus, many more pixels and the treatability of both brain hemispheres to increase the field of view and visual quality, he noted.

To facilitate the accelerated program, Second Sight has a 3- to 5-year plan that is focusing on the organizational structure; adding positions in research and development, quality control, repertory affairs, and clinical research; and making changes in the supply chain and manufacturing capabilities.

Technologic improvements envisioned by McGuire for the visual cortical prosthesis system include electronics enhancements so that many more electrodes can be used, i.e., a 169-channel chip compared with the current 60.

Other complementary technologies to artificial vision being pursued by Second Sight are object and facial recognition software, which will inform the user of what or who is the viewed object, and infrared imaging, in which the stimulated vision is produced by heat to facilitate locations of objects.

McGuire is hopeful about reimbursements by the Centers for Medicare and Medicaid Services (CMS) as a result of the Breakthrough Device designation and the potential for an add-on automatic payment by CMS for 2 years with the designation.

### WHAT ABOUT ARGUS II?

Second Sight Medical Products remains committed to supporting existing Argus II users including pursuing regulatory approvals for the Argus IIs next-generation externals, according to McGuire.

"We have next-generation externals, Argus IIs, under development that include new eyewear, camera, and more powerful VPU to upgrade the current patients," he said. "We will supply eyewear and VPU replacements as needed."

"Personnel will be available to evaluate the technology and provide changes to the settings to optimize the vision as it changes over time," he said, and forecasts the new externals to be available before the end of 2019. ■

#### NADER POURATIAN, MD, PHD

E: npouratian@mednet.ucla.edu

Dr. Pouratian is a consultant to Second Sight Medical Products.

#### JESSY D. DORN, PHD

E: jdorn@2-sight.com

Dr. Dorn is an employee of Second Sight Medical Products.

#### ROBERT GREENBERG, MD, PHD

Dr. Greenberg is a consultant to Second Sight Medical Products.

## The Edward S. Harkness Eye Institute

## PRECISION OPHTHALMOLOGY 2020

# APPLYING GENETICS TO EYE CARE TODAY

Program Chairs:  
Irene Maumenee, MD  
Stephen H. Tsang, MD, PhD

## Save the Date

December 6, 2019  
The University Club  
1 West 54th Street  
New York City

[Columbiaeye.org/  
Precision2020](http://Columbiaeye.org/Precision2020)

This activity has been approved for AMA PRA Category 1 Credit™

COLUMBIA UNIVERSITY  
DEPARTMENT OF  
OPHTHALMOLOGY

 COLUMBIA  
OPHTHALMOLOGY

 NewYork-Presbyterian

# Laser therapy maintains position as key DME treatment option

Amid introduction of new technologies, device still playing critical role

By Lynda Charters; Reviewed by Elias Reichel, MD

**LASER REMAINS** A critical component in the treatment of diabetic macular edema (DME) amid an increasing number of new devices designed to deliver subthreshold laser.

“Laser still plays a very important role in the treatment of diabetic macular edema despite our reliance on anti-vascular endothelial drugs,” said Elias Reichel, MD, professor of ophthalmology and vice chairman, Tufts University School of Medicine, Boston.

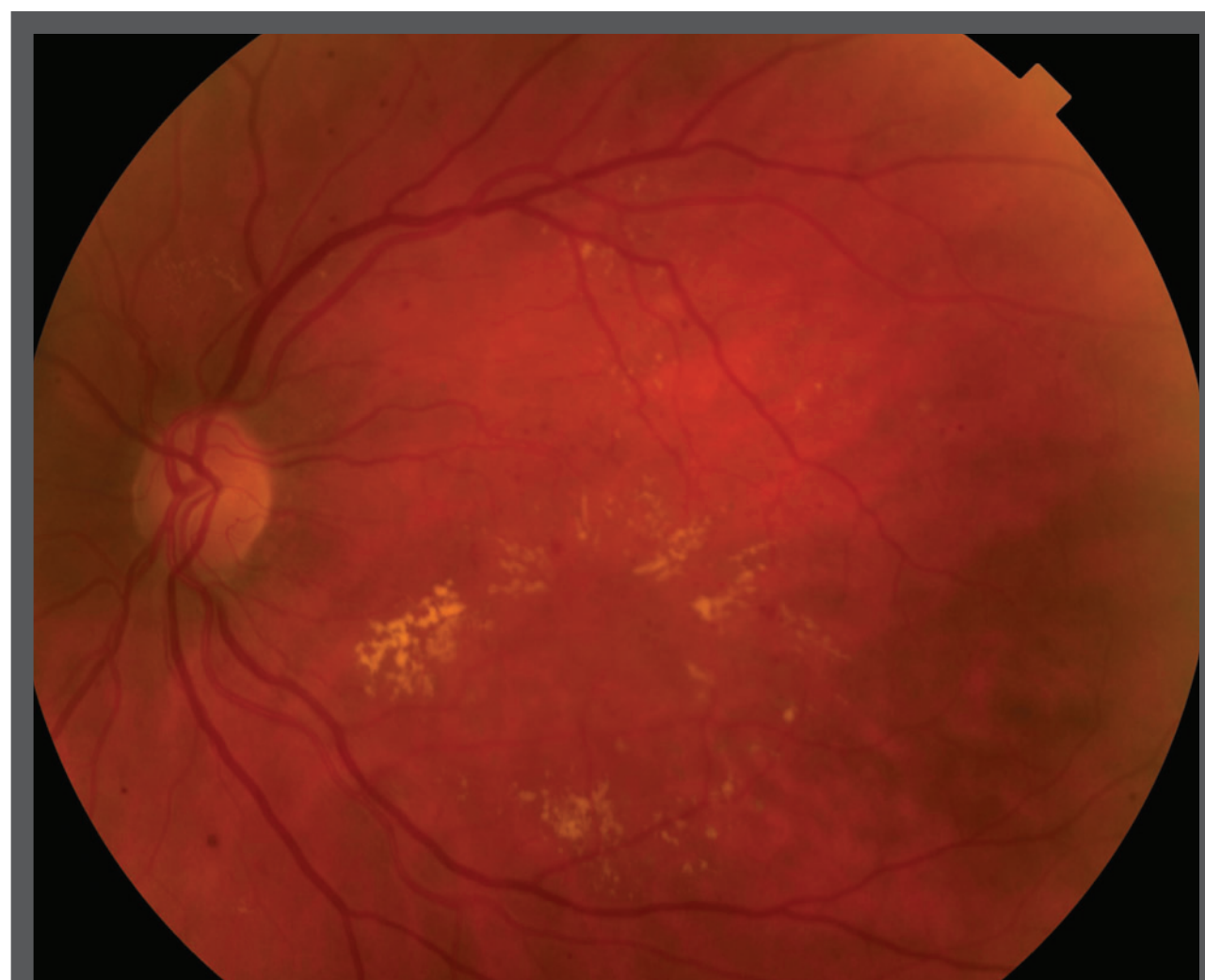
The Diabetic Retinopathy Clinical Research Network (DRCR.net) Protocol I study supports that statement, with patients treated with deferred laser therapy, defined as application between 24 weeks, fared the best. Over the course of two years, Dr. Reichel pointed out, there was a benefit in those patients compared with those treated promptly with laser, and accompanied by anti-VEGF or steroid therapy and sham treatment. As an additive therapy, laser is helpful even in DRCR.net Protocol T compared to primary VEGF therapy.

Subthreshold laser is defined as that which shows no signs of damage to the clinical examiner, Dr. Reichel explained, and demonstrated what constitutes subthreshold laser therapy. In a patient with 20/50 visual acuity (VA), fluorescein angiography (FA) showed diffuse leakage through the macula, and optical coherence tomography (OCT) showed the cystic change. The patient

was treated with micropulse laser in the left eye with the setting of 400 mW, 200 μm spot size, for 200 ms; 343 spots were applied, which is seven applications on a 7 x 7 grid. An important factor in this treatment was the 5% duty cycle, which has been able to perform subthreshold laser treatment safely even with application to the fovea, he emphasized.

## TAKE-HOME

► **Laser continues to play an important role in diabetic macular edema amid an increasing reliance on anti-VEGF drugs.**



A patient with diabetic macular edema with vision at 20/100 is a primary candidate for laser. (Photos courtesy of Elias Reichel, MD)

Four months after laser treatment, the VA was 20/30. No changes resulting from the treatment or pigmentary changes were visible on fluorescein angiography. The foveal appearance on OCT was more normal than before treatment with some small central cysts visible.

All of the basic science research has supported subthreshold laser; however,

the clinical efficacy is supported only by limited case series, which provided data on Micropulse and Endpoint Management (Topcon Medical Systems, Inc.), he commented. The usefulness of laser demonstrated in the DRCR.net concerned conventional laser photocoagulation only.

“It is important to understand that micropulse therapy can be applied to the fovea in patients with DME, but Endpoint Management and microbubble disruption avoids the fovea,” he said.

**FDA APPROVED DEVICES**

The devices approved in the United States all use yellow or green wavelengths.

Three micropulse devices have been approved. They include Micropulse (IRI-DEX), Quantel Laser (SubLuminal), and Lumenis (SmartPulse).

Topcon makes continuous-wave technology (Endpoint Management). Ellex manufactures Retinal Rejuvenation Therapy (2RT), a microbubble disruption therapy.

Compared with conventional laser—

Continues on page 16 : **Laser**


# Let Us Be Your *Eyes and Ears*



## **Introducing EyePod: Podcasts from *Ophthalmology Times***

This new audible resource from *Ophthalmology Times* engages with key opinion leaders in interviews about the latest innovations in the areas of surgery, clinical diagnosis, pharmaceutical advancements, research, and technology, plus practice management.

Hear the voices of ophthalmic innovation.  
**[OphthalmologyTimes.com/EyePod](http://OphthalmologyTimes.com/EyePod)**



# INNOVATION IN SIGHT

Novartis is an industry leader in reimagining medicine.

**OVER  
4 MILLION**  
US prescriptions  
filled in 2018

**Visit us at ASRS!**  
Find Novartis at booth #512  
and learn more about our commitment to retina.

**Reference:** Data on file. Novartis Pharmaceuticals Corp; 2019.





# Setting expectations for glaucoma patients having cataract surgery

Pearls can ensure physicians get best outcomes, help patients set realistic goals

By *Vanessa Caceres*; Reviewed by *Anup Khatana, MD*

**SETTING EXPECTATIONS FOR** patients and physicians before cataract surgery in advanced glaucoma cases was one of eight pearls shared by Yvonne Ou, MD, associate professor of ophthalmology and co-director of the glaucoma service, Department of Ophthalmology, UCSF, San Francisco. Dr. Ou focused her pearls on advanced glaucoma patients having cataract surgery.



Dr. Ou

“All of us know many of these tips, but taken together, they can help minimize vision loss,” she said.

Here are Dr. Ou’s eight pearls:

## 1. USE CAREFUL SURGICAL PLANNING

Part of this planning process is deciding whether to do a staged procedure with glaucoma surgery per-

formed first or do a combined procedure.

“Cataract surgery after a filtering procedure may pose a risk to the bleb, but combined surgery also may make some parts of surgery easier,” Dr. Ou said.

One option is performing cataract surgery alone, while another pre-surgical plan involves IOL selection.

“Most of us will choose a monofocal IOL, but it’s also worthwhile to consider a toric,” she said.

There is research that shows greater astigmatic correction and good visual outcomes with the use of toric IOLs in this patient group, but be careful with this choice in patients who have pseudoexfoliation, Dr. Ou cautioned.

Dr. Ou also noted that physicians should avoid multifocal IOLs in advanced glaucoma patients.

## 2. MANAGE EXPECTATIONS

Physicians also should consider consenting for cataract surgery with or without bleb revision.

“Patients with well-controlled or low IOP are less likely to have an IOP drop,” Dr. Ou said.

## 3. TAKE STEPS PROPHYLACTICALLY TO AVOID AN IOP SPIKE

Patients with a longer axial length, prior laser trabeculoplasty, or who used a larger number of medications were more likely to have a spike in previous research, Dr. Ou reported.

Oral acetazolamide, Miostat, and a topical beta blocker or a combination drop of beta blocker and carbonic anhydrase inhibitor all are options to help protect against IOP spikes.

## 4. MINIMIZE INFLAMMATION

“Use all the methods at your disposal for a nice, dilated pupil,” Dr. Ou advised.

Efforts to minimize inflammation could include visco dilation with Healon5 or several other iris expansion techniques. Thorough cortex removal also is important.

*Continues on page 18 : Glaucoma*

## TAKE-HOME

► **With planning and strategic use of surgical tips and techniques, physicians can lower the chance for vision loss in advanced glaucoma patients having cataract surgery.**

## LASER

(Continued from page 14)

characterized by a solid block of laser application over time (100 or 200 ms) accompanied by a temperature increase—the heat produced is absorbed by the retinal pigment epithelium (RPE) and choriocapillaris and is in turn diffused into the neurosensory retina with the potential to cause damage.

Micropulse therapy is a packet of energy that is delivered over 200 ms; the laser is on 5% of the time and off 95% of the time in the individual packets.

“There is an increase in temperature; the retinal tissue heat, but they cool rapidly, and there is no diffusion damage to the neurosensory retina,” Dr. Reichel said.

According to Dr. Reichel, Endpoint Management differs from Micropulse because it relies on the Arrhenius integral and describes the changes in temperature in time and space over biologic tissues in response to laser energy.

“This technology uses a short-pulse duration

within a narrow therapeutic window and the biologic damage is proportional to the laser power,” he explained.

The algorithm that is used in this technology results in a spot that shows barely visible damage. The power setting then drops 70% to reach the perfect level of treatment energy and duration for surgeons to use.

Dr. Reichel provided an example in with the energy level was about 30% for 12 ms.

Microbubble disruption provides selective targeting of individual RPE cells.

The microbubbles around the melanosomes expand, causing intracellular damage resulting in individual cell apoptosis.

The adjacent RPE cells migrate, divide, and produce new RPE cells.

Dr. Reichel commented that there are no landmark burns in these technologies except for the those produced by the algorithm used in Endpoint Management.

The others rely on physician titration, which necessitates that they observe retinal burns.

## PRACTICAL TIPS

According to Dr. Reichel, physicians use the correct preset, confirm the correct treatment mode and make sure the laser is not set to the conventional treatment mode. They also should confirm the 5% duty cycle setting when using Micropulse, and be aware of landmarks and placement of treatment spots.

“Several different subthreshold technologies are available,” he said.


However, Dr. Reichel noted that the administration of subfoveal therapy is only possible with Micropulse.

“The ability to perform Micropulse and the recommended titration and the appropriate protocol and settings should be confirmed with the manufacturer,” he concluded. “No clinical trials have been conducted to confirm the superiority or noninferiority of Micropulse to conventional laser with any of the subthreshold technologies.” ■

## ELIAS REICHEL, MD

E: [ereichel@tufts.nemc.org](mailto:ereichel@tufts.nemc.org)

Dr. Reichel is a consultant to Lutronics, a member of the speakers' bureau for IRIDEX, and received a research grant from Lumenis.



# nurture THEIR EYES



Take a fresh approach to treating dry eye symptoms with FRESHKOTE® Preservative Free (PF)

**Patented polymer blend** of polyvinyl alcohol and povidone supports all layers of the tear film<sup>1,2</sup>

**Triple-acting formula** reduces evaporation and increases stability of the tear film while high oncotic pressure draws excess water from epithelial cells<sup>1,3</sup>

**Compatible for use with contact lenses**<sup>4</sup>

**State-of-the-art multidose bottle** provides more than a month's worth of preservative-free drops when dosed 4 times a day<sup>5</sup>

RECOMMEND SOOTHING RELIEF

Visit [FRESHKOTEPF.com](https://www.freshkote.com) to learn more

FRESHKOTE®  
Preservative Free  
LUBRICANT EYE DROPS

**References:** 1. Holly FJ. Lacrophilic ophthalmic demulcents. *US Ophthalmic Rev.* 2007;3:38-41. 2. FRESHKOTE Drug Facts. Eyevance Pharmaceuticals LLC; 2018. 3. Holly FJ. *Colloidal Osmosis — Oncotic Pressure.* Grapevine, TX: Dry Eye Institute; 2006. 4. Fuller DG, Connor CG. Safety and efficacy of FreshKote® used as a rewetting agent in Lotrafilcon-A® contact lens wearers. Poster presented at: American Academy of Optometry Annual Meeting; November 17-20, 2010; San Francisco, CA. 5. Nemera. Novelia®. <https://nemera.net/products/ophthalmic-novelvia-eyedropper/>. Accessed March 14, 2019.



© 2019 Eyevance Pharmaceuticals LLC. All rights reserved.  
FRESHKOTE® is a registered trademark of Eyevance Pharmaceuticals LLC.  
Novelia® is a registered trademark of Nemera Development.  
FPF-19-AD-05.00

# Hypotony more than just a number; consider symptoms during therapy

While numerous techniques are available to surgeons, awareness is important

By Lynda Charters; Reviewed by Eydie G. Miller-Ellis, MD

**HYPOTONY, LOW IOP** after surgery, can have an adverse impact on a patient's vision. It is defined as an IOP of 5 mm Hg or less and generally occurs in the early postoperative timeframe, during periods of overfiltration. It can last for a few weeks.

Chronic hypotony, while not uncommon, is another ball of wax because it can persist for longer than three months postoperatively. The Tube versus Trabeculectomy Study found that about 13.5% of patients had chronic hypotony, but only about half experienced associated adverse effects, according to Eydie G. Miller-Ellis, MD, chief, Glaucoma Service, and professor of Clinical Ophthalmology, Scheie Eye Institute, University of Pennsylvania Perelman School of Medicine, Philadelphia.

Numerous techniques are available to avoid chronic hypotony, but Dr. Miller-Ellis noted that awareness of the condition is important.

"We are concerned with choroidal expansion, which occurs when the IOP is lower than the intravascular pressure, and there is an elevated risk of choroidal detachment, hypotony maculopathy, and other associated complications," she pointed out.

Not everyone has adverse effects as the result of an IOP below 5 mm Hg.

Some patients can feel well in that scenario. On the flip side, clinical hypotony is the scenario in which a patient with low IOP experiences associated visual or ocular side effects, Dr. Miller-Ellis explained.

## MONITORING IOP

When patients have progressive disease at IOPs of 12 or 15 mm Hg, clinicians want to establish an IOP at a level low enough to decrease the stress on the lamina and the retinal nerve fibers to preserve the



**'When the IOP is low, the globe can become deformed with every blink or eye rubbing and they develop visual symptoms based on that.'**

— Eydie Miller-Ellis, MD

vision and possibly improve the blood flow. However, while the not-too-low IOP value makes the clinician happy, he or she has to be concerned about how the patient is feeling and rule out any associated complications.

The signs associated with choroidal expansion—shallowing of the anterior chamber, choroidal detachment, choroidal hemorrhage, long-term hypotony maculopathy—are issues.

"The bigger concerns, even in patients who do not have visible choroidal detachments or hypotony maculopathy, are that they can have blurred fluctuating vision and some ocular discomfort," Dr. Miller-Ellis said. "When the IOP is low, the globe can become

deformed with every blink or eye rubbing and they develop visual symptoms based on that."

Hypotony resulting from a big bleb can also cause bleb dysesthesia—dry eye or tear film disruption—which is even more problematic for many patients.

## RISK FACTORS

One complication, hypotony maculopathy, tends to develop more often in association with male gender, younger age, myopia, after a primary filtering surgery, in a phakic patient, and in Caucasians. Choroidal detachments tend to occur more often in older patients and shorter eyes, Dr. Miller-Ellis explained.

## CASES

Dr. Miller-Ellis described a representative case of a 54-year-old Caucasian man with pigmentary glaucoma, 4.0 diopters of myopia, and a corneal thickness of 520  $\mu\text{m}$ .

*Continues on page 19 : Hypotony*

## GLAUCOMA

(Continued from page 16)

### 5. REMOVE VISCOELASTIC MATERIAL

Viscoelastic is necessary to maintain the anterior chamber depth throughout the procedure, especially in hyperopic eyes and those with prior filtering surgery. Complete removal can be a challenge, but take the extra time to do it, especially in high myopes, Dr. Ou said.

Make sure to also remove viscoelastic material behind the IOL. A technique from Uday Devgan, MD, called angle sweep shows a way to help remove

viscoelastic material and is available on the website CataractCoach.com, Dr. Ou said.

### 6. PROTECT AND/OR REVIVE

Avoid manipulation of the bleb, and consider adding a 5-fluorouracil injection at the end of the case and during postoperative visits. To get a sense of bleb function intraoperatively, trypan blue can be used but is not always predictive, Dr. Ou said.

### 7. MAINTAIN CLOSE FOLLOW-UP

Spikes in IOP can occur four to six hours after surgery, so consider same-day postoperative visits for at-risk patients or a close follow-up to monitor for IOP spikes.

### 8. CONSIDER USE OF STEROIDS

The use of ophthalmic steroids are especially key if the surgeon sees early indications of bleb failure, Dr. Ou explained.

Ophthalmic steroids, usually eye drops, gels, or ointments, are made to be administered in or around the eye. They also treat inflammation and relieve symptoms that can include pain, swelling, irrigation and redness. ■

#### YVONNE OU, MD

E: [Yvonne.Ou@ucsf.edu](mailto:Yvonne.Ou@ucsf.edu)

This article was adapted from Dr. Ou's presentation at the American Glaucoma Society annual meeting. Dr. Ou is a consultant for Merck.

## HYPOTONY

( Continued from page 18 )

The patient underwent bilateral trabeculectomies with mitomycin C in 2005 and 2006. The IOP remained under control until 2013, when it began to increase to the upper teens in one eye. The IOP increase was refractory to medical therapy. Bleb needling resulted in an IOP of 1 mm Hg. Months after the needling, the IOP remained low, between 2 and 3 mm Hg.

The patient's vision was "quite good," (20/25) without choroidal effusions or hypotony maculopathy despite the patient reporting some visual fluctuations and slightly less ocular comfort than the fellow eye that were not problematic for him.

A second case was that of a 70-year-old Caucasian woman who had undergone trabeculectomy with mitomycin C in the right eye four years earlier. The IOP in that eye was 8 mm Hg. The vision was 20/20 and the visual field was stable. There was no evidence of dellen. Despite the excellent clinical picture, the patient was extremely uncomfortable as a result of a persistent foreign body sensation.

The patient had been referred for surgery in the other eye, but she refused because of the status of the right eye.

"Even if the corneal surface is good and there is no evident choroidal expansion, treating the surface disease is necessary to increase the patient's comfort before another intervention is considered," Dr. Miller-Ellis explained.

'Even without choroidal detachments or hypotony maculopathy, we must focus on the patients' symptoms.' – Eydie Miller-Ellis, MD

The third case was that of an 80-year-old African-American woman who underwent a phaco-trabeculectomy and had an initial IOP of 4 mm Hg with a shallow anterior chamber.

By six weeks postoperatively, the IOP remained low but the anterior chamber had deepened and at six months postoperatively the IOP was 5 mm Hg. The outcome was good, with 20/25 vision, no choroidal expansion, and a deep anterior chamber.

The last case was that of a 69-year-old Caucasian woman who underwent a trabeculectomy with mitomycin C

13 years earlier.

The bilateral IOPs were 4 mm Hg, but she complained of poor vision with acuities of 20/80 and 20/25 in the right and left eyes, respectively, with mild cataracts. The refraction was moderate myopia with a corneal thickness of 510 μm. The patient had turned down bleb revision surgeries on multiple occasions.

Dr. Miller-Ellis recounted that the patient had significant bilateral hypotony maculopathy with folds extending through the macula to the periphery.

Over time, the vision has deteriorated further because of the cataracts. However, there is little chance of the vision returning to normal with IOP normalization since the maculopathy is longstanding, but cataract surgery might provide some improvement.

When you consider how low the IOP can go, Dr. Miller-Ellis noted that the ideal goal might be between 8 to 12 mm Hg because you can maximize the protective effect of the IOP and maintain functional vision.

"Even without choroidal detachments or hypotony maculopathy, we must focus on the patients' symptoms," she concluded. "They need to feel well in order to accept that the surgery has been successful for them. While risk factors can be identified in our patients, they are individuals and can be unpredictable." ■

### TAKE-HOME

► **Managing hypotony is not based on the intraocular pressure alone. Symptoms are a big consideration and must be accounted for during treatment.**

### FOR MORE FROM OPHTHALMOLOGY TIMES

Find us on all of these platforms

Join the discussion at [Facebook.com/OphthalmologyTimes](https://www.facebook.com/OphthalmologyTimes)

Follow us @[OphthTimes](https://twitter.com/OphthTimes)

See more images at [Instagram.com/OphthalmologyTimes](https://www.instagram.com/OphthalmologyTimes)

Listen to full interviews at [Soundcloud.com/OphthalmologyTimes](https://www.soundcloud.com/OphthalmologyTimes)

Watch more surgical procedures and pearls at [YouTube.com/OphthalmologyTimes](https://www.youtube.com/OphthalmologyTimes)

EYDIE G. MILLER-ELLIS, MD

E: [eydie.miller-ellis@uphs.upenn.edu](mailto:eydie.miller-ellis@uphs.upenn.edu)

Dr. Miller-Ellis has no financial interest in any aspect of this report.

**The 18<sup>th</sup> Annual Downeast Ophthalmology Symposium**  
**SEPTEMBER 20-22, 2019**  
**Bar Harbor, Maine**

**For further information, contact:**  
 Shirley Goggin  
 Maine Society of Eye Physicians and Surgeons  
 P.O. Box 190, Manchester, ME 04351  
 Tel: 207-445-2260 • [sgoggin@mainemed.com](mailto:sgoggin@mainemed.com)  
[www.maineeyemds.com](http://www.maineeyemds.com)

# Refractive Cataract Surgery: Optimizing visual quality

Francis S. Mah, MD



Dr. Mah is director of Cornea Service and co-director of Refractive Surgery Service, Scripps Clinic, La Jolla, CA. He is a paid consultant to Johnson & Johnson Surgical Vision, Inc.

When ophthalmologists enter into practice, they often continue using the techniques and technologies they became familiar with during their training. In the interest of optimizing care, however, it is worthwhile throughout our careers to take a critical look at our processes and procedures to identify opportunities for improvement.

Applying that concept to cataract surgery, choices exist for all the different technologies that are currently used. Uniquely, however, the intraocular lens (IOL) is the only device that is left behind with the patient, and it has a lifelong impact on the patient's vision. On that basis, I consider the IOL as "my signature" in cataract surgery and I want to be certain that I implant the best technology available.

We are fortunate today that excellent results can be achieved with all modern foldable IOLs. Based on careful evaluation of material and design issues as these relate to vision, though, I am confident that I can optimize functional outcomes for my patients and their satisfaction by choosing an implant from the TECNIS® (Johnson & Johnson Surgical Vision) portfolio of lenses.

## Technical analysis of the TECNIS® IOLs

Hitting the refractive target is fundamental for delivering a good visual acuity outcome after cataract surgery. Nevertheless, providing durably good functional vision goes beyond Snellen acuity. It also depends on the quality of the image.

### Contrast sensitivity

Contrast sensitivity has a key role in image quality and therefore functional vision. Spherical aberration of the visual system is an important determinant of contrast sensitivity. In fact, findings from a bench experiment conducted using an adaptive optics vision simulator show that peak contrast performance is achieved through the elimination of spherical aberration.<sup>1</sup>

TECNIS® monofocal IOLs were the first IOLs designed to reduce total ocular spherical aberration. In 2006, because of clear evidence that this innovation improved functional vision and contrast acuity, the Centers for Medicare & Medicaid Services created "reduced spherical aberration" as a new class of new technology intraocular lenses.<sup>2</sup> Today, all TECNIS® IOLs feature a modified prolate anterior surface incorporating  $-0.27 \mu\text{m}$  of negative spherical aberration that totally compensates for the average positive spherical aberration in the human cornea.<sup>3</sup>

Aspheric IOLs available from other manufacturers have either zero spherical aberration or less negative spherical aberration than the TECNIS® IOLs. Therefore, these IOLs

leave the average pseudophakic eye with some positive spherical aberration.

### Chromatic aberration

Chromatic aberration, which is a function of optic material, also affects image quality. Chromatic aberration is the dispersion of visible light into its component wavelengths. Thus, its correction restores sharp focus of the light waves and crisp image quality.

The amount of chromatic aberration in an optic material is described by its Abbe number.<sup>4</sup> A higher Abbe number indicates a lower amount of chromatic aberration that translates into better optical quality.<sup>4</sup> The Abbe number of the hydrophobic acrylic material used for the TECNIS® IOLs is 55, which compares very favorably with the Abbe number of the hydrophobic acrylic material used for AcrySof® (Alcon), which is only 37.<sup>4</sup>

### Glistenings

The presence of glistenings in an IOL is another factor that can affect visual function after cataract surgery. Glistenings are fluid (water)-filled microvacuoles that form within the IOL optic when the implant is in an aqueous environment.<sup>5</sup> By impairing light propagation through the optic and increasing retinal straylight, glistenings have the potential to cause hazy vision, increased glare hindrance, loss of contrast and color, and halos around bright light sources.<sup>6,7</sup>

In a prospective, randomized clinical trial comparing TECNIS® (ZCB00) and AcrySof® IQ (SN60WF) IOLs in fellow eyes, glistenings appeared more frequently and in larger quantities in the AcrySof® IQ IOLs than in the TECNIS® IOLs, and the glistenings in the AcrySof® IQ IOLs increased between visits at 2 and 3 years. Only a few TECNIS® IOLs developed glistenings that were smaller in number and did not increase over time.<sup>8</sup> Consistent with the clinical experience are the results of a laboratory study in which investigators used experimental methods to induce glistenings in IOLs.<sup>6</sup> The research compared 4 commercially available hydrophobic acrylic lenses: AcrySof®, iSymm™ (Hoya Surgical Optics), enVista® (Bausch + Lomb), and TECNIS®. It found that significant glistenings, defined as glistenings associated with straylight levels exceeding those of a healthy 20-year-old crystalline lens, were present only in the AcrySof® and iSymm™ IOLs. TECNIS® IOLs were not associated with glistenings.

### Anterior capsule changes

Anterior capsule opacification and anterior capsular contraction are other issues that can affect visual outcomes long term after IOL implantation. These problems are believed to arise as a result of metaplasia and fibrosis of residual lens epithelial cells (LECs) and can affect the refractive and visual outcome by obstructing the visual axis and causing a shift in IOL position.<sup>9</sup>

Published evidence shows that the development and degree of anterior capsule opacification and anterior cap-

sular contraction are less with the TECNIS® IOL compared with the AcrySof® platform.<sup>8-10</sup> The difference between these implants may be explained by material compositional and design differences.<sup>8-10</sup> For example, investigators propose that the 360° square edge of the TECNIS® IOL may prevent LEC migration between the anterior capsule and the IOL compared with the interrupted square edge design of the AcrySof® IOL.<sup>8</sup>

### Meeting the needs of modern patients

In my opinion, the TECNIS® portfolio offers the broadest range of lens technology built on the high quality optics and material. I appreciate the availability of the different models because this increases my ability to personalize vision for individuals and meet the diverse vision correction and lifestyle needs of the heterogeneous cataract surgery patient population.

Patients who are prioritizing vision at far and intermediate distances because of their active lifestyle and reliance on digital technologies are part of a growing trend in my practice. The TECNIS Symfony® or TECNIS Symfony® Toric extended-depth-of-focus IOLs have proved a valuable addition in allowing me to address the visual needs of these patients.

I have also been using the TECNIS Symfony® IOLs with another lens in the TECNIS® family as part of a personalized approach to vision restoration after cataract surgery. For example, when a patient is interested in presbyopia correction, I implant a TECNIS Symfony® or TECNIS Symfony® Toric IOL in the first eye and then determine whether the patient is satisfied with his or her vision at all distances. If the patient indicates a desire for better near vision, I have been successful meeting that goal by implanting a +3.25-D TECNIS® Multifocal IOL in the fellow eye. I have found that it does not matter whether I operate on the dominant or nondominant eye first when I am using a TECNIS Symfony® IOL. Therefore, I have no concerns if I have to divert from an initial plan for bilateral TECNIS Symfony® IOL implantation.

### Conclusion

A host of IOL material and design characteristics affect visual quality after cataract surgery. Understanding these issues and how they differ across implant technologies provides a foundation for choosing IOLs that will optimize the functional outcomes of patients and their surgical satisfaction.

In my view, TECNIS® IOLs have advantages when it comes to spherical and chromatic aberration correction, glistenings, and anterior capsule opacification or capsular contraction. Importantly, as the bottom line, I am consistently achieving excellent clinical results and making patients very happy using TECNIS® IOLs in my practice.

### REFERENCES

- Piers PA, Manzanera S, Prieto OM, Gorceix N, Artal P. Use of adaptive optics to determine the optimal ocular spherical aberration. *J Cataract Refract Surg.* 2007;33(10):1721-1726.
- Centers for Medicare & Medicaid Services. CMS announces approval of new technology intraocular lens. January 26, 2006. Available at: <https://www.cms.gov/newsroom/press-releases/cms-announces-approval-new-technology-intraocular-lens>. Accessed June 19, 2019.
- TECNIS® 1-Piece ZCB00 DFU.
- Zhao H, Mainster MA. The effect of chromatic dispersion on pseudophakic optical performance. *Br J Ophthalmol.* 2007;91(9):1225-1229.
- Werner L. Glistenings and surface light scattering in intraocular lenses. *J Cataract Refract Surg.* 2010;36(8):1398-1420.
- van der Mooren M, Franssen L, Piers P. Effects of glistenings in intraocular lenses. *Biomed Opt Express.* 2013;4(8):1294-1304.
- Beiko G. Glistenings and retinal straylight. *J Cataract Refract Surg.* 2012;38(12):2212-2213.
- Johansson B. Glistenings, anterior/posterior capsular opacification and incidence of Nd:YAG laser treatments with two aspheric hydrophobic acrylic intraocular lenses—a long-term intra-individual study. *Acta Ophthalmol.* 2017;95(7):671-677.
- Kahraman G, Ferdinano C, Wetzel B, et al. Intraindividual comparison of capsular behavior of 2 hydrophobic acrylic intraocular lenses during a 5-year follow-up. *J Cataract Refract Surg.* 2017;43(2):228-233.
- Hartman M, Rauser M, Brucks M, Chalam KV. Evaluation of anterior capsular contraction syndrome after cataract surgery with commonly used intraocular lenses. *Clin Ophthalmol.* 2018;12:1399-1403.

## TECNIS 1 Piece IOL

### Rx Only

**INDICATIONS:** TECNIS® 1-Piece IOL lenses are indicated for the visual correction of aphakia in adult patients in whom a cataractous lens has been removed by extracapsular cataract extraction. These devices are intended to be placed in the capsular bag.

**PRECAUTIONS:** Do not resterilize the lens. Most sterilizers are not equipped to sterilize the soft acrylic material without producing undesirable side effects. Do not soak or rinse the intraocular lens with any solution other than sterile balanced salt solution or sterile normal saline. Do not store the lens in direct sunlight or at a temperature greater than 113°F (45°C). Do not autoclave the intraocular lens. Please refer to the specific instructions for use provided with the insertion instrument or system for the amount of time the IOL can remain folded before the IOL must be discarded. When the insertion system is used

improperly, the haptics of the TECNIS® 1-Piece IOL may become damaged.

**WARNINGS:** Physicians considering lens implantation should weigh the potential risk/benefit ratio for any conditions described in the TECNIS® 1-Piece IOL Directions for use that could increase complications or impact patient outcomes. These conditions include recurrent severe anterior or posterior segment inflammation or uveitis; patients in whom the intraocular lens may affect the ability to observe, diagnose or treat posterior segment diseases; surgical difficulties at the time of cataract extraction, which may increase the potential for complications (e.g., persistent bleeding, significant iris damage, uncontrolled positive pressure or significant vitreous prolapse or loss); a compromised eye due to previous trauma or developmental defects in which appropriate support of the IOL is not possible; circumstances that would result

in damage to the endothelium during implantation; suspected microbial infection; or patients in whom neither the posterior capsule nor the zonules are intact enough to provide support for the IOL. Children under the age of 2 years are not suitable candidates for intraocular lenses. The TECNIS® 1-Piece IOL should not be placed in the ciliary sulcus.

**ADVERSE EVENTS:** In 3.3% of patients, reported adverse events of cataract surgery with the TECNIS® 1-Piece IOL included macular edema. Other reported reactions occurring in less than 1% of patients were secondary surgical intervention (pars plana vitrectomy with membrane peel) and lens exchange (due to torn lens haptic).

**ATTENTION:** Reference the Directions for Use for a complete listing of indications and important safety information.

## INDICATIONS and IMPORTANT SAFETY INFORMATION for TECNIS SYMFONY and TECNIS SYMFONY TORIC EXTENDED RANGE OF VISION IOLs

### Rx Only

**INDICATIONS FOR USE:** The TECNIS Symphony Extended Range of Vision IOL, Model ZXR00, is indicated for primary implantation for the visual correction of aphakia, in adult patients with less than 1 diopter of pre-existing corneal astigmatism, in whom a cataractous lens has been removed. The lens mitigates the effects of presbyopia by providing an extended depth of focus. Compared to an aspheric monofocal IOL, the lens provides improved intermediate and near visual acuity, while maintaining comparable distance visual acuity. The Model ZXR00 IOL is intended for capsular bag placement only. The TECNIS Symphony Toric Extended Range of Vision IOLs, Models ZXT150, ZXT225, ZXT300, and ZXT375, are indicated for primary implantation for the visual correction of aphakia and for reduction of residual refractive astigmatism in adult patients with greater than or equal to 1 diopter of preoperative corneal astigmatism, in whom a cataractous lens has been removed. The lens mitigates the effects of presbyopia by providing an extended depth of focus. Compared to an aspheric monofocal IOL, the lens provides improved intermediate and near visual acuity, while maintaining comparable distance visual acuity. The Model Series ZXT IOLs are intended for capsular bag placement only.

**WARNINGS:** Patients with any of the conditions described

in the Directions for Use may not be suitable candidates for an intraocular lens because the lens may exacerbate an existing condition, may interfere with diagnosis or treatment of a condition, or may pose an unreasonable risk to the patient's eyesight. Lenses should not be placed in the ciliary sulcus. May cause a reduction in contrast sensitivity under certain conditions, compared to an aspheric monofocal IOL; fully inform the patient of this risk before implanting the lens. Special consideration should be made in patients with macular disease, amblyopia, corneal irregularities, or other ocular disease. Inform patients to exercise special caution when driving at night or in poor visibility conditions. Some visual effects may be expected due to the lens design, including: a perception of halos, glare, or starbursts around lights under nighttime conditions. These will be bothersome or very bothersome in some people, particularly in low-illumination conditions, and on rare occasions, may be significant enough that the patient may request removal of the IOL.

Rotation of the TECNIS Symphony Toric IOLs away from their intended axis can reduce their astigmatic correction, and misalignment >30° may increase postoperative refractive cylinder. If necessary, lens repositioning should occur as early as possible prior to lens encapsulation.

**PRECAUTIONS:** Interpret results with caution when refracting using autorefractors or wavefront aberrometers that

utilize infrared light, or when performing a duochrome test. Confirmation of refraction with maximum plus manifest refraction technique is recommended. The ability to perform some eye treatments (e.g. retinal photocoagulation) may be affected by the optical design. Target emmetropia for optimum visual performance. Care should be taken to achieve IOL centration, as lens decentration may result in a patient experiencing visual disturbances under certain lighting conditions. For the TECNIS Symphony Toric IOL, variability in any preoperative surgical parameters (e.g. keratometric cylinder, incision location, surgeon's estimated surgically induced astigmatism and biometry) can influence patient outcomes. Carefully remove all viscoelastic and do not over-inflate the capsular bag at the end of the case to prevent lens rotation.

**SERIOUS ADVERSE EVENTS:** The most frequently reported serious adverse events that occurred during the clinical trial of the TECNIS Symphony lens were cystoid macular edema (2 eyes, 0.7%) and surgical reintervention (treatment injections for cystoid macular edema and endophthalmitis, 2 eyes, 0.7%). No lens-related adverse events occurred during the trial.

**ATTENTION:** Reference the Directions for Use for a complete listing of Indications and Important Safety Information.

## INDICATIONS AND IMPORTANT SAFETY INFORMATION FOR THE TECNIS Multifocal Family of 1-Piece IOLs

### Rx Only

**INDICATIONS:** The TECNIS Multifocal 1-Piece intraocular lenses are indicated for primary implantation for the visual correction of aphakia in adult patients with and without presbyopia in whom a cataractous lens has been removed by phacoemulsification and who desire near, intermediate, and distance vision with increased spectacle independence. The intraocular lenses are intended to be placed in the capsular bag.

**WARNINGS:** Physicians considering lens implantation should weigh the potential risk/benefit ratio for any conditions described in the Directions for Use that could increase complications or impact patient outcomes. Multifocal IOL

implants may be inadvisable in patients where central visual field reduction may not be tolerated, such as macular degeneration, retinal pigment epithelium changes, and glaucoma. The lens should not be placed in the ciliary sulcus. Inform patients about the possibility that a decrease in contrast sensitivity and an increase in visual disturbances may affect their ability to drive a car under certain environmental conditions, such as driving at night or in poor visibility conditions.

**PRECAUTIONS:** Prior to surgery, inform prospective patients of the possible risks and benefits associated with the use of this device and provide a copy of the patient information brochure to the patient. The long term effects of in-

traocular lens implantation have not been determined. Secondary glaucoma has been reported occasionally in patients with controlled glaucoma who received lens implants. Do not reuse, resterilize or autoclave.

**ADVERSE EVENTS:** The rates of surgical re-interventions, most of which were non-lens related, were statistically higher than the FDA grid rate for both the ZMB00 (+4.00 D) and ZLB00 (+3.25 D) lens models. For the ZMB00, the surgical re-intervention rates were 3.2% for first eyes and 3.3% for second eyes. The reintervention rate was 3.3% for both the first and second eyes in the ZLB00 group.

**ATTENTION:** Reference the Directions for Use for a complete listing of Indications and Important Safety Information.

# LASIK surgery continues to thrive, offering positive outcomes

Surgeons use procedure to offer patients improved vision quickly with few side effects

By Robert K. Maloney, MD; Special to Ophthalmology Times

**LASIK IS BETTER** than ever, despite reports that have highlighted poor outcomes, most from years ago. Data actually shows that LASIK results are better than ever and patients can expect outstanding results, with few side effects. In our practice, LASIK is thriving.

While I never promise patients a particular outcome, I am up-front that our goal is to get to better than 20/20 vision. I can say this with confidence because my colleagues and I recently reported on a multicenter clinical trial in which more than three-quarters of eyes, and more than 90% of patients when measured binocularly, had uncorrected visual acuity of 20/16 or better.<sup>1</sup>

Patients are interested to hear this. The idea of “better than 20/20” is the part of a consultation that gets them excited.

Refractive surgery results have reached this point because we have seen consistent, incremental improvements in laser vision correction technology. Wavefront-guided procedures, tighter control of laser energy and laser beam angle, and other technical improvements have greatly increased the proportion of 20/20 or better outcomes and reduced the variability in results.

Newer platforms have also nearly eliminated the quality-of-vision complaints related to optical aberrations (e.g., double vision, hazy vision, disabling glare) that we sometimes saw after LASIK.

Patients have an unerring radar for a surgeon’s level of confidence. Based on my own data and what is in the published literature, I don’t have to give patients a lot of qualifiers about the results they can expect. Of course, I always warn them about possible side effects, but the numbers—and the confidence I feel—communicate that my level of concern is low.

## PROSPECTIVE STUDY

The study I mentioned was an investigator-initiated, post-market study conducted by Colman Kraff, MD, Stephen Coleman, MD, and myself. In all, 97 patients were enrolled in this prospective study to evaluate the results of wavefront-guided LASIK using an aberrometer (iDesign, Johnson & Johnson Vision) to guide the treatment. All subjects underwent bilateral LASIK, with a target of emmetropia. Nomogram adjustments were made as needed to bring the wavefront sphere into agreement with the manifest refraction sphere.

Of the 97 patients enrolled, 84 completed the study. Preoperative spherical error ranged from  $-0.25$  D to  $-11.0$  D (mean  $-3.83$  D), with or without astigmatism of up to  $-5.0$  D. Subjects were examined at baseline, one, three, and six months postoperatively.

Ninety-seven percent of eyes achieved postop monocular uncorrected visual acuity of 20/20 or better; 77% were 20/16 or better. When vision was measured binocularly, all subjects could see at least 20/20, with 93% seeing 20/16 or better.

The mean manifest refraction at six months was  $-0.01$  D, with a standard deviation of 0.25 D, the mean manifest cylinder was  $-0.21$  D.

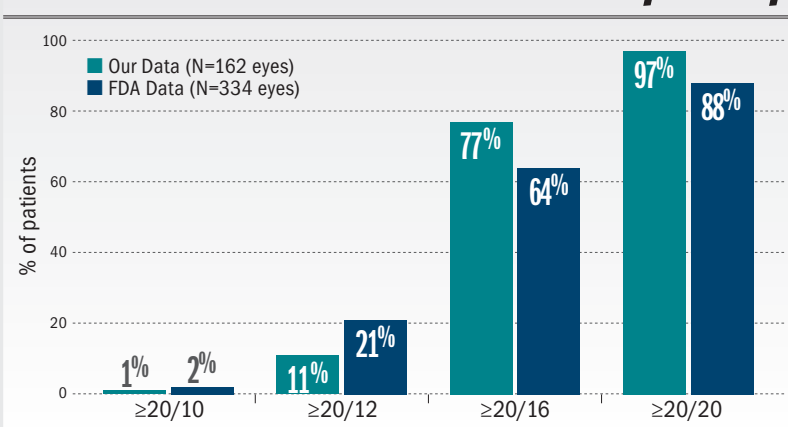
At six months, about half the patients reported that their eyes never felt dry or gritty, while half said they “sometimes” felt dry or gritty. Only 4% reported more frequent symptoms.

At six months, most patients also reported rarely experiencing glare, halo, starbursts, or double vision. The rate of these symptoms decreased compared to baseline. Patient reports of starbursts declined from 15% of subjects before surgery to 1.5% after. Reports of halos decreased from 9.7% preop to 3% postop.

## TAKE-HOME

► In a multicenter clinical trial, more than 90 percent of patient, when measured binocularly, had uncorrected visual acuity of 20/16 or better.

## Monocular UCVA 6 months postop



The chart shows LASIK visual acuity results achieved at Dr. Maloney's practice compared to FDA data. (chart courtesy of Robert K. Maloney, MD)

Ninety-six percent of subjects said they could function with “no difficulty” without corrective lenses, and 97% said their quality of life had improved. Nearly all subjects (99%) said they would recommend LASIK to a friend or relative.

## STANDARD DEVIATION

Although our mean postoperative manifest refraction was nearly zero, the most impressive aspect of the results is the standard deviation (SD) of 0.25 D.

Standard deviation of the manifest refraction spherical equivalent (MRSE) is the way we should judge a laser system.

Let us compare two hypothetical lasers. Laser One has a mean MRSE of 0.00 D with a relatively high SD of 0.36 D. Eighty-four percent of eyes are within 0.5 D of emmetropia.

Hypothetical Laser Two has an inaccurate mean MRSE at  $-0.3$  D, but a lower SD. Laser Two also achieves 84% of eyes within 0.5 D of emmetropia.

Obviously you would choose Laser Two, and you would program a simple nomogram adjustment of 0.3 D. You would be the owner of a system than got 99% of eyes within 0.5 D of emme-

tropia. The large standard deviation of Laser One is not correctable. This is why standard deviation of MRSE should be a key measure of a laser’s performance.

We know that each extra line of uncorrected vision translates into a jump in patient satisfaction. To build a LASIK practice that thrives on high satisfaction and patient referrals, 20/20 is not enough. You really need to get patient after patient to 20/15—and that is possible with today’s wavefront technology. ■

## REFERENCE

1. Maloney RK, Kraff CR, Coleman SC. A prospective multicenter post-approval study of wavefront-guided LASIK for myopia using a high-def Hartmann-Shack aberrometer. ASCRS, 2019.



**ROBERT K. MALONEY, MD**

E: [rm@maloneyvision.com](mailto:rm@maloneyvision.com)

Dr. Maloney is director, Maloney Vision

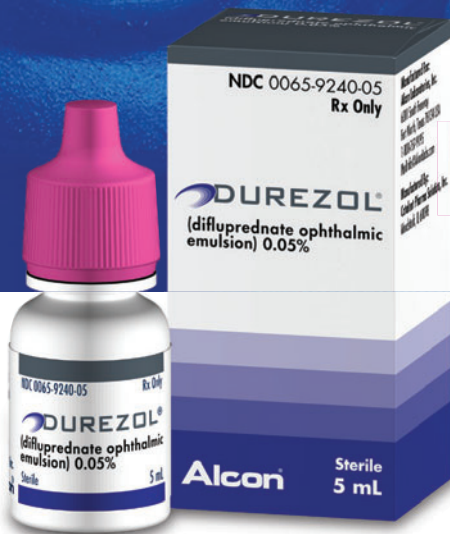Institute; clinical professor of ophthalmology,

David Geffen School of Medicine at UCLA Los Angeles. He is a consultant to Johnson & Johnson Vision.

# A POTENT THERAPY FOR THE TREATMENT OF INFLAMMATION AND PAIN FOLLOWING OCULAR SURGERY

✦ A potent and  
consistent  
formulation<sup>1-3</sup>

✦ Excellent managed  
care coverage<sup>4</sup>  
• 90% commercial lives  
• 94% Medicare Part D lives



Eligible commercial patients now pay as little as **\$30\***

Not actual patients.

Explore the potency and proven efficacy of DUREZOL<sup>®</sup> Emulsion at [durezolhcp.com](http://durezolhcp.com).

## IMPORTANT SAFETY INFORMATION

### Contraindications

DUREZOL<sup>®</sup> Emulsion, as with other ophthalmic corticosteroids, is contraindicated in most active viral diseases of the cornea and conjunctiva including epithelial herpes simplex keratitis (dendritic keratitis), vaccinia, and varicella, and also in mycobacterial infection of the eye and fungal diseases of ocular structures.

### Warnings and Precautions

- **Intraocular pressure (IOP) increase** – Prolonged use of corticosteroids may result in glaucoma with damage to the optic nerve, defects in visual acuity and fields of vision. If this product is used for 10 days or longer, IOP should be monitored.
- **Cataracts** – Use of corticosteroids may result in posterior subcapsular cataract formation.
- **Delayed healing** – The use of steroids after cataract surgery may delay healing and increase the incidence of bleb formation. In those diseases causing thinning of the cornea or sclera, perforations have been known to occur with the use of topical steroids. The initial prescription and renewal of the medication order beyond 28 days should be made by a physician only after examination of the patient with the aid of magnification such as slit lamp biomicroscopy and, where appropriate, fluorescein staining.

## INDICATIONS AND USAGE

DUREZOL<sup>®</sup> (difluprednate ophthalmic emulsion) 0.05% is a topical corticosteroid that is indicated for:

- The treatment of inflammation and pain associated with ocular surgery.
- The treatment of endogenous anterior uveitis.

## Dosage and Administration

- For the treatment of inflammation and pain associated with ocular surgery instill one drop into the conjunctival sac of the affected eye 4 times daily beginning 24 hours after surgery and continuing throughout the first 2 weeks of the postoperative period, followed by 2 times daily for a week and then a taper based on the response.
- For the treatment of endogenous anterior uveitis, instill one drop into the conjunctival sac of the affected eye 4 times daily for 14 days followed by tapering as clinically indicated.

• **Bacterial infections** – Prolonged use of corticosteroids may suppress the host response and thus increase the hazard of secondary ocular infections. In acute purulent conditions, steroids may mask infection or enhance existing infection. If signs and symptoms fail to improve after 2 days, the patient should be re-evaluated.

• **Viral infections** – Employment of a corticosteroid medication in the treatment of patients with a history of herpes simplex requires great caution. Use of ocular steroids may prolong the course and may exacerbate the severity of many viral infections of the eye (including herpes simplex).

• **Fungal infections** – Fungal infections of the cornea are particularly prone to develop coincidentally with long-term local steroid application. Fungus invasion must be considered in any persistent corneal ulceration where a steroid has been used or is in use.

• **Contact lens wear** – DUREZOL<sup>®</sup> Emulsion should not be instilled while wearing contact lenses. Remove contact lenses prior to instillation of DUREZOL<sup>®</sup> Emulsion. The preservative in DUREZOL<sup>®</sup> Emulsion may be absorbed by soft contact lenses. Lenses may be reinserted after 10 minutes following administration of DUREZOL<sup>®</sup> Emulsion.

## Most Common Adverse Reactions

- In postoperative ocular inflammation and pain studies, ocular adverse reactions occurring in 5-15% of subjects included corneal edema, ciliary

and conjunctival hyperemia, eye pain, photophobia, posterior capsule opacification, anterior chamber cells, anterior chamber flare, conjunctival edema, and blepharitis.

- In the endogenous anterior uveitis studies, the most common adverse reactions occurring in 5-10% of subjects included blurred vision, eye irritation, eye pain, headache, increased IOP, iritis, limbal and conjunctival hyperemia, punctate keratitis, and uveitis.

**For additional information about DUREZOL<sup>®</sup> Emulsion, please see Brief Summary of Prescribing Information on adjacent page.**

\*Limitations apply. For commercially insured patients. Up to a \$155 cap per bottle. Patient will be responsible for any co-pay once limit per bottle is reached. **This offer is not valid under Medicare, Medicaid, or any other federal or state program. Not valid for cash-paying patients.** Novartis reserves the right to rescind, revoke, or amend this program without notice. Additional terms and conditions apply. Please see co-pay materials for details.

**References:** 1. Durezol [package insert]. Fort Worth, TX: Alcon Laboratories, Inc; 2017. 2. Stringer W, Bryant R. Dose uniformity of topical corticosteroid preparations: difluprednate ophthalmic emulsion 0.05% versus branded and generic prednisolone acetate ophthalmic suspension 1%. *Clin Ophthalmol*. 2010;4(1):1119-1124. 3. Korenfeld MS, Silverstein SM, Cooke DL, Vogel R, Crockett RS; Difluprednate Ophthalmic Emulsion 0.05% (Durezol) Study Group. Difluprednate ophthalmic emulsion 0.05% for postoperative inflammation and pain. *J Cataract Refract Surg*. 2009;35(1):26-34. 4. Fingertip Formulary, January 2018.



**DUREZOL® (difluprednate ophthalmic emulsion) 0.05%**  
**Initial U.S. Approval: 2008**

**BRIEF SUMMARY: Please see package insert for full prescribing information.**

## **1 INDICATIONS AND USAGE**

### **1.1 Ocular Surgery**

DUREZOL® (difluprednate ophthalmic emulsion) 0.05%, a topical corticosteroid, is indicated for the treatment of inflammation and pain associated with ocular surgery.

### **1.2 Endogenous Anterior Uveitis**

DUREZOL is also indicated for the treatment of endogenous anterior uveitis.

## **4 CONTRAINDICATIONS**

The use of DUREZOL, as with other ophthalmic corticosteroids, is contraindicated in most active viral diseases of the cornea and conjunctiva including epithelial herpes simplex keratitis (dendritic keratitis), vaccinia, and varicella, and also in mycobacterial infection of the eye and fungal disease of ocular structures.

## **5 WARNINGS AND PRECAUTIONS**

### **5.1 Intraocular pressure (IOP) Increase**

Prolonged use of corticosteroids may result in glaucoma with damage to the optic nerve, defects in visual acuity and fields of vision. Steroids should be used with caution in the presence of glaucoma. If this product is used for 10 days or longer, IOP should be monitored.

### **5.2 Cataracts**

Use of corticosteroids may result in posterior subcapsular cataract formation.

### **5.3 Delayed Healing**

The use of steroids after cataract surgery may delay healing and increase the incidence of bleb formation. In those diseases causing thinning of the cornea or sclera, perforations have been known to occur with the use of topical steroids. The initial prescription and renewal of the medication order beyond 28 days should be made by a physician only after examination of the patient with the aid of magnification such as slit lamp biomicroscopy and, where appropriate, fluorescein staining.

### **5.4 Bacterial Infections**

Prolonged use of corticosteroids may suppress the host response and thus increase the hazard of secondary ocular infections. In acute purulent conditions, steroids may mask infection or enhance existing infection. If signs and symptoms fail to improve after 2 days, the patient should be reevaluated.

### **5.5 Viral Infections**

Employment of a corticosteroid medication in the treatment of patients with a history of herpes simplex requires great caution. Use of ocular steroids may prolong the course and may exacerbate the severity of many viral infections of the eye (including herpes simplex).

### **5.6 Fungal Infections**

Fungal infections of the cornea are particularly prone to develop coincidentally with long-term local steroid application. Fungus invasion must be considered in any persistent corneal ulceration where a steroid has been used or is in use. Fungal culture should be taken when appropriate.

### **5.7 Topical Ophthalmic Use Only**

DUREZOL is not indicated for intraocular administration.

### **5.8 Contact Lens Wear**

DUREZOL should not be instilled while wearing contact lenses. Remove contact lenses prior to instillation of DUREZOL. The preservative in DUREZOL may be absorbed by soft contact lenses. Lenses may be reinserted after 10 minutes following administration of DUREZOL.

## **6 ADVERSE REACTIONS**

The following serious reactions are found elsewhere in the labeling:

- Elevated IOP [see *Warnings and Precautions (5.1)*]
- Posterior subcapsular cataract formation [see *Warnings and Precautions (5.2)*]
- Secondary ocular infection [see *Warnings and Precautions (5.4)*]
- Perforation of the globe [see *Warnings and Precautions (5.3)*]

## **6.1 Ocular Surgery**

Ocular adverse reactions occurring in 5% to 15% of subjects in clinical studies with DUREZOL included corneal edema, ciliary and conjunctival hyperemia, eye pain, photophobia, posterior capsule opacification, anterior chamber cells, anterior chamber flare, conjunctival edema, and blepharitis. Other ocular adverse reactions occurring in 1% to 5% of subjects included reduced visual acuity, punctate keratitis, eye inflammation, and iritis. Ocular adverse reactions occurring in less than 1% of subjects included application site discomfort or irritation, corneal pigmentation and striae, episcleritis, eye pruritus, eyelid irritation and crusting, foreign body sensation, increased lacrimation, macular edema, sclera hyperemia, and uveitis. Most of these reactions may have been the consequence of the surgical procedure.

## **6.2 Endogenous Anterior Uveitis**

A total of 200 subjects participated in the clinical trials for endogenous anterior uveitis, of which 106 were exposed to DUREZOL. The most common adverse reactions of those exposed to DUREZOL occurring in 5% to 10% of subjects included blurred vision, eye irritation, eye pain, headache, increased IOP, iritis, limbal and conjunctival hyperemia, punctate keratitis, and uveitis. Adverse reactions occurring in 2% to 5% of subjects included anterior chamber flare, corneal edema, dry eye, iridocyclitis, photophobia, and reduced visual acuity.

## **8 USE IN SPECIFIC POPULATIONS**

### **8.1 Pregnancy Teratogenic Effects**

#### **Pregnancy Category C**

Difluprednate has been shown to be embryotoxic (decrease in embryonic body weight and a delay in embryonic ossification) and teratogenic (cleft palate and skeletal anomalies) when administered subcutaneously to rabbits during organogenesis at a dose of 1-10 mcg/kg/day. The no-observed-effect-level (NOEL) for these effects was 1 mcg/kg/day, and 10 mcg/kg/day was considered to be a teratogenic dose that was concurrently found in the toxic dose range for fetuses and pregnant females. Treatment of rats with 10 mcg/kg/day subcutaneously during organogenesis did not result in any reproductive toxicity, nor was it maternally toxic. At 100 mcg/kg/day after subcutaneous administration in rats, there was a decrease in fetal weights and delay in ossification, and effects on weight gain in the pregnant females. It is difficult to extrapolate these doses of difluprednate to maximum daily human doses of DUREZOL, since DUREZOL is administered topically with minimal systemic absorption, and difluprednate blood levels were not measured in the reproductive animal studies. However, since use of difluprednate during human pregnancy has not been evaluated and cannot rule out the possibility of harm, DUREZOL should be used during pregnancy only if the potential benefit justifies the potential risk to the embryo or fetus.

### **8.3 Nursing Mothers**

It is not known whether topical ophthalmic administration of corticosteroids could result in sufficient systemic absorption to produce detectable quantities in breast milk. Systemically administered corticosteroids appear in human milk and could suppress growth, interfere with endogenous corticosteroid production, or cause other untoward effects. Caution should be exercised when DUREZOL is administered to a nursing woman.

### **8.4 Pediatric Use**

DUREZOL was evaluated in a 3-month, multicenter, double-masked trial in 79 pediatric patients (39 DUREZOL; 40 prednisolone acetate) 0 to 3 years of age for the treatment of inflammation following cataract surgery. A similar safety profile was observed in pediatric patients comparing DUREZOL to prednisolone acetate ophthalmic suspension, 1%.

### **8.5 Geriatric Use**

No overall differences in safety or effectiveness have been observed between elderly and younger patients.

U.S. Pat.: [www.alconpatents.com](http://www.alconpatents.com)

©2013, 2016 Novartis

Distributed by:

Alcon Laboratories

Fort Worth, Texas 76134 USA

T2017-52

April 2017

# Facing challenge of corneal infection management in operated eyes

Early identification, aggressive treatment critical; when to consider surgical intervention

By Cheryl Guttman Krader; Reviewed by Bennie H. Jeng, MD, MS

**CORNEAL INFECTIONS INVOLVING** surgical interfaces and incisions represent special situations that mandate special considerations for successful management, said Bennie H. Jeng, MD, MS.

Dr. Jeng is professor and chairman, Department of Ophthalmology and Visual Sciences, University of Maryland School of Medicine, Baltimore. He discussed the issues and treatment approaches for corneal infections associated with corneal grafts, flaps, and surgical incisions.

“There is a high risk for progressive infection and/or wound dehiscence in these clinical situations,” he said. “Early identification and aggressive treatment of the infection are critical, and surgical intervention might also need to be considered.”

## PENETRATING KERATOPLASTY

The inflammatory response accompanying an infectious corneal ulcer in an eye that has had penetrating keratoplasty (PK) can cause endothelial cell dysfunction and subsequently graft failure. Infection can also develop around loose sutures and lead to graft loss secondary to tissue destruction or graft dehiscence.

Use of topical corticosteroids, presence of eyelid/adnexal abnormalities or epithelial defects, and bandage contact lens wear can also lead to late infection in eyes with a full thickness graft.

Management of corneal infections in post-PK eyes includes obtaining a specimen for culture, aggressive treatment with fortified antibiotics, and consideration for reduction in topical corticosteroid use. Suture removal is needed in cases involving suture abscess.

“If the infection is large and progressive, threatening the graft-host interface, I will try to excise it en bloc and re-graft the cornea if it is not responding to medical therapy appropriately,” Dr. Jeng said.

Infections that develop in a Descemet stripping automated endothelial keratoplasty or Descemet’s membrane endothelial keratoplasty interface tend to appear a few weeks to a few months after the graft procedure and usually have a fungal etiology, with *Candida* being the most common pathogen. In addition to the clinical appearance, confocal microscopy can be helpful for making the diagnosis.

Excision of the donor lenticule and surrounding infected tissue followed by PK provides definitive treatment, but alternative management approaches have also been described. The latter include removing the endothelial graft, irrigating the anterior chamber with amphotericin B, and then repeating the endo-

thelial keratoplasty procedure after the infection has been adequately treated. Intrastromal injections of antifungal agents have also been suggested.

“These infections are deep-seated, and topical and oral antifungals are not very effective treatments because they do not penetrate to the infection site when administered by these routes,” Dr. Jeng said.

Infections in a deep anterior lamellar keratoplasty (DALK) interface are also most often caused by fungi. Bacterial infections can also occur and usually develop in the setting of incomplete removal of infected stroma when the grafting was performed in an eye with active infectious keratitis.

Confocal microscopy can aid in the diagnosis, and PK represents the most definitive treatment. Intrastromal injection of an antimicrobial agent can also be considered. As for interface infections in endothelial keratoplasty (EK), infections in the DALK interface are deep-seated, and as such, topical and oral therapies are not usually adequate.

“Irrigation of the interface after graft removal will probably not be effective because there will still be infected stromal tissue,” Dr. Jeng said.

## USING KERATOPROSTHESIS

When a corneal infection develops in an eye with a keratoprosthesis, there is special concern that it will progress to involve tissue underneath the collar of the device where penetration of topically applied antimicrobial agents will be poor. There is a risk the infection will migrate along the stem of the optic into the eye, causing endophthalmitis.

Management requires scraping to obtain a specimen for culture and smear with attention to trying to scrape underneath the device’s flange if there is involvement in that area. Topical fortified antibiotics and antifungals should be administered. Corneal crosslinking is being investigated as a possible treatment for these infections

“I would not hesitate to remove the keratoprosthesis and perform PK if I was concerned about perforation, endophthalmitis, or spread toward the graft-host interface,” Dr. Jeng said.

Implantation of another keratoprosthesis can be considered only after the eye has become quiet.

Infections in a LASIK interface that develop within the first 1 to 2 weeks after surgery are usually caused by gram-positive bacteria, whereas atypical microorganisms (especially *Mycobacteria* but also fungi) are the common causes of infections appearing later.

## LASIK INTERFACE

Because LASIK interface infections are superficial, they can be managed by lifting, scraping, and irrigating the flap. Considering the risk for mycobacterial infection, material obtained for Gram stain and culture in eyes with a late infection should be cultured on Lowenstein-Jensen media, in addition to standard media, Dr. Jeng said.

Patients with a LASIK interface infection should also be started on fortified antibiotic drops, and a topical fluoroquinolone might be added. In cases with late presentation where there is concern about an atypical pathogen, treatment should include amikacin and discontinuation of topical corticosteroids. For fungal infections, preferred agents are natamycin or voriconazole if the organism is a filamentous fungus while

amphotericin B is used for yeast infections.

“Intervention in the worst-case scenario would be to do a therapeutic PK,” Dr. Jeng said.

Incision infections after cataract surgery generally present within the first week and can be caused by bacteria, fungi, or atypical mycobacteria. These infections are abscess-like and recommended management involves incision and scraping for culture, done in a minor room or operating room.

Intensive topical antimicrobial treatment and possibly intrastromal administration of antimicrobials is indicated.

“If the infection is extending to the limbus, I would not hesitate to do an early lamellar excision if it will remove the involved tissue,” he said. “If it is too late, then the involved tissue can be removed and replaced with a small full-thickness graft.” ■

## TAKE-HOME

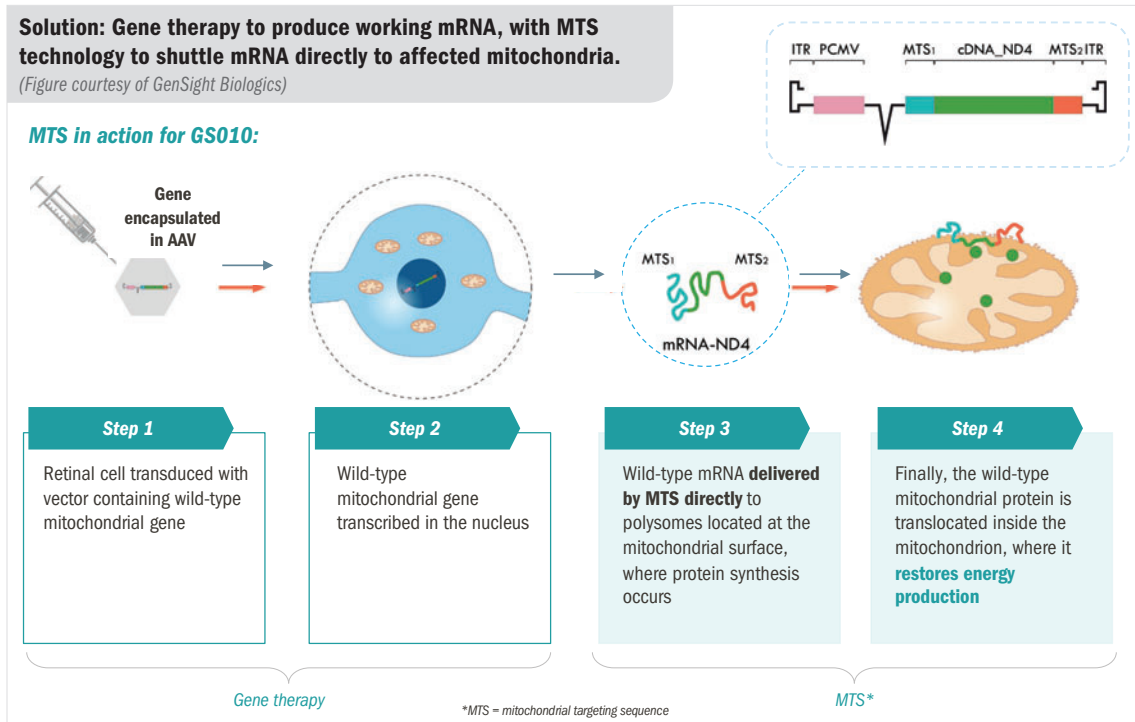
► **Corneal infections involving surgical interfaces and incisions represent high-stakes situations. Bennie H. Jeng, MD, MS discusses diagnosis and management of these challenging situations.**

**BENNIE JENG, MD, MS**

**E:** [bjeng@som.maryland.edu](mailto:bjeng@som.maryland.edu)

This article was adapted from Dr. Jeng’s presentation at Cornea Subspecialty Day during AAO 2018. Dr. Jeng has no relevant financial interests to disclose.

ADVANCES CONTINUE TO PROGRESS FOR INNOVATIVE TREATMENTS IN GENETICS



Jr., EyeBrain Center, Thomas Jefferson University, Philadelphia, which is the central reading center for the GS010 phase III studies.

Dr. Sergott said the researchers could not fully explain the results from the GS010 trials.

“There is reason to be encouraged, however, and to be hopeful that as we go forward and more data become available, we will begin to better understand the outcomes,” he explained.



Dr. Sergott

GS010 is a recombinant adeno-associated viral vector serotype 2 containing the wild-type ND4 gene. In both RESCUE and REVERSE, enrolled patients received a single intravitreal injection of GS010 in one randomly selected eye and a sham injection in the fellow eye.

The primary outcome measure in RESCUE looked at ETDRS best-corrected visual acuity (BCVA) at week 48 post-injection.

To meet the primary endpoint, the results had to show a +15-letter difference in BCVA favoring the GS010-treated eyes compared to sham.

The primary endpoint analysis showed, however, that there was essentially no difference between groups. Eyes treated with GS010 had a mean BCVA loss of 19 ETDRS letters compared with baseline while on average, sham-treated eyes had a loss of 20 ETDRS letters.

As expected and consistent with the natural history of LHON, mean BCVA in both groups declined after study entry and reached a nadir. The GS010-treated eyes achieved a mean BCVA improvement of 13 ETDRS letters relative to the nadir while sham-treated eyes improved by a mean of 11 letters.

Data from RESCUE that supports the efficacy of GS010 included the finding that GS010-treated eyes were threefold more likely than sham-treated eyes to have 20/200 or better BCVA at week 48 ( $p=0.0247$ ).

In addition, an analysis comparing outcomes between fellow eyes in individual patients showed that the change from baseline of high-contrast visual acuity was at least 0.3 LogMar (15 ETDRS letters) better in the treated eye than in the sham-treated eye in 24% of subjects.

A similar result was obtained in an analysis comparing improvements in low-contrast visual acuity, which is a more sensitive measure of visual function than high-contrast visual acuity, said Dr. Sergott.

#### INTERPRETING THE DATA

Various factors may explain why the RESCUE trial did not meet its primary efficacy endpoint. Premature timing of the evaluation is one possibility.

RESCUE entered patients who were early in the course of their disease when there is typically rapid neuronal degeneration and loss of vision.

Because it takes time after GS010 injection for the gene to be incorporated into cells and for the cells to begin to express functioning proteins, week 48 may have been too early to find a statistically significant difference in BCVA change from baseline between study groups.

*Continues on page 28 : LHON data*

# LHON GENE THERAPY: DECIPHERING PHASE III DATA

## Secondary outcome measures provide signals of efficacy

By Cheryl Guttman Krader; Reviewed by Robert C. Sergott, MD

### take-home

► Phase III studies of a gene therapy for Leber hereditary optic neuropathy have generated some unexpected positive findings. There is biologic plausibility to explain the data.

**R**ESCUE, the phase III study investigating GS010 (GenSight Biologics) for Leber hereditary optic neuropathy (LHON) due to the G11778A ND4 mitochondrial mutation in patients with up to six months of vision loss, did not meet its primary endpoint.

Data from secondary outcome measures and from a longer follow-up in RESCUE and in a completed phase 3 trial that enrolled patients with a longer history of vision loss (REVERSE), however, provide strong signals of efficacy, including a potential benefit in untreated fellow eyes.

The collective clinical trial experience also shows that the gene therapy is well-tolerated and has an acceptable safety profile.

“The GS010 phase III trials are rigorously designed and conducted studies, and any well-done clinical trial often generates unexpected findings,” said Robert C. Sergott, MD, director, Wills Eye Hospital, Neuro-Ophthalmology and founding director, William H. Annesley,



**WHEN IT'S CLOUDY  
AS CAN BE, YOUR  
CHOICE COULDN'T  
BE MORE CLEAR.**

**IT'S BETTER WITH  
BLUE ON YOUR SIDE.**

When faced with complex and challenging cases, cataract surgeons know right where to look. The only FDA-approved cataract stain, VisionBlue® has been proven in more than 6 million cases around the world – delivering the kind of safe and reliable results surgeons know they can count on when it matters most. See what your peers are saying about VisionBlue®, the leading Trypan Blue cataract stain, visit [blueonyourside.com](http://blueonyourside.com)

**VisionBlue®**

VISIONBLUE® 0.06% (TRYPAN BLUE OPHTHALMIC SOLUTION)

By **DORC**

You are encouraged to report negative side effects of prescription drugs to the FDA. Visit [www.fda.gov/medwatch](http://www.fda.gov/medwatch), or call 1-800-FDA-1088.

**INDICATIONS AND USAGE** VisionBlue® 0.06% is indicated for use as an aid in ophthalmic surgery by staining the anterior capsule of the lens. **DOSAGE AND ADMINISTRATION** **Cataract surgery** VisionBlue® 0.06% is packaged in a 2.25 mL syringe to which a blunt cannula has to be attached. After opening the eye, an air bubble is injected into the anterior chamber of the eye in order to minimize dilution of VisionBlue® 0.06% by the aqueous. VisionBlue® 0.06% is carefully applied onto the anterior lens capsule using a blunt cannula. Sufficient staining is achieved as soon as the dye has contacted the capsule. The anterior chamber is then irrigated with balanced salt solution to remove all excess dye. An anterior capsulotomy can then be performed. **DOSAGE FORMS AND STRENGTHS** VisionBlue® (trypan blue ophthalmic solution) 0.06% is supplied in 2.25 mL syringes filled to a volume of 0.5 mL. **WARNINGS AND PRECAUTIONS** Excessive staining: It is recommended that after injection all excess VisionBlue® 0.06% is immediately removed from the eye by thorough irrigation of the anterior chamber. **ADVERSE REACTIONS** Adverse reactions reported following use of VisionBlue® 0.06% include discoloration of high water content hydrogen intraocular lenses [see Contraindications] and inadvertent staining of the posterior lens capsule and vitreous face. Staining of the posterior lens capsule or staining of the vitreous face is generally self limited, lasting up to one week.

# Unraveling role of genetics in the pathogenesis of diabetic retinopathy

Sixty-five genes identified with several belonging to signaling pathways

By Lynda Charters

**DIABETIC RETINOPATHY (DR)** is a major retinal microvascular complication of diabetes and while much is known about DR, the mechanisms underlying its etiology remain a mystery.

With this part of the puzzle still unsolved, the treatments that presently are available for DR are inadequate because they cannot reverse or prevent the ocular complications of diabetes.

Investigators from the Medical College of Georgia, Augusta University, led by Ashok Sharma, PhD, of the Center for Biotechnology and Genomic Medicine and the Department of Population Health Sciences, took the next step in the evaluation of 65 genes that had been identified in association with DR.

## DIVING DEEPER

The genes were identified by linkage analysis, candidate gene association, and genome-wide association studies.

Most of these genes that are associated with DR had been identified through candidate gene-based association studies, according to investigators.

Dr. Sharma and associates hoped that mapping them to biologic processes and pathways, they

could add to the understanding of the functional role of these genes in the pathogenesis of DR, the authors explained.

The genetic analysis performed in the current study found that most of these genes belong to various biologic pathways that make a significant contribution to the pathogenesis of DR.

## TAKE-HOME

► **Genetic factors play a key role in the onset and progression of diabetic retinopathy.**

These include insulin signaling, angiogenesis (hypoxia-inducible factor-1 signaling, regulation of blood vessel size, vascular endothelial growth factor signaling), inflammation (interleukin-6 signaling, leukocyte adhesion, transforming growth factor-B, and tumor necrosis factor signaling), lipid metabolic process, neurogenesis (neural cell differentiation, neurotrophin signaling), and protein kinase signaling (Jak-STAT, P13K-Akt, MAPK, Ras, and mTOR signaling).

Another important area identified was the genes' impact on regulation of endothelial cell/leukocyte interaction (cell adhesion molecules, cell migration).

## GENETIC FACTORS

The investigators reported their findings in *Eye* (<https://doi.org/10.1038/s41433-019-0337-y>).

"In this review, we compiled a comprehensive list of genetic factors associated with DR. Further analyses revealed the biological functions of these genes in DR pathogenesis," the investigators said. "The identification of genetic factors and their contribution to DR etiology will allow for tailored pharmacogenomics approaches for the treatment of DR."

The authors added that DR is a microvascular disease of the retina and the leading cause of visual disability in patients with diabetes.

"Genetic factors have [been] shown to play a pivotal role in DR onset, and several candidate genes have been associated with its progression," they concluded. "This review presents an insight into genes associated with DR and their role in various biological functions and signaling pathways."

Their hope is that the information reported in this analysis will aid in unraveling the role of genetics in the pathogenesis of DR. ■

## ASHOK SHARMA, PHD

E: [shsharma@augusta.edu](mailto:shsharma@augusta.edu)

The authors reported no conflicts of interest associated with this report. The research was supported by a grant to Dr. Sharma from the National Institutes of Health/National Eye Institute.

## LHON DATA

(Continued from page 26)

A plot of the trajectories of visual acuity in RESCUE participants shows that BCVA declined in both GS010- and sham-treated eyes for four to five months after injection, which is consistent with what is known about the natural history of the disease. After reaching a nadir, BCVA remained more stable in the sham-treated eyes but was on an improving trend in the GS010-treated group at the week 48 visit.

"Remarkably indeed, additional analyses of outcomes in RESCUE after 72 weeks show that the eyes are tracking together in terms of showing continuing recovery of BCVA," Dr. Sergott said.

At week 72, which is the second scheduled readout of the RESCUE data, GS010-treated eyes improved

by 21 ETDRS letters from nadir. Sham-treated eyes closely tracked GS010-treated eyes, improving 21.7 ETDRS letters equivalent from nadir. In both study groups, 40% of eyes improved by a clinically meaningful difference (+15 ETDRS letters), from nadir.

Further evidence to support the idea that a treatment benefit may be identified over time comes from the REVERSE trial that investigated GS010 in patients who had vision loss for six to 12 months before receiving treatment. In this cohort of patients who were more likely to have entered a chronic phase of disease characterized by less rapid vision loss, BCVA improved by a mean of 11 ETDRS letters from baseline to week 48, both in GS010-treated eyes and the sham-treated contralateral control eyes.

By week 96, BCVA in the GS010-treated eyes had improved by a mean of 15.4 ETDRS letters compared with baseline, representing a gain of 28.1 ETDRS letters relative to the worst vision.

While BCVA improvement in sham-treated eyes in the GS010 trials was somewhat of a surprise, access of GS010 into the control eye is a more plausible explanation than spontaneous recovery, he said.

"Cases of spontaneous vision improvement in patients with LHON are infrequent, and OCT imaging has shown us that from the time of onset of vision loss, there is not spontaneous structural recovery in the retina or optic nerve," he explained.

Data from 96 weeks of follow-up in REVERSE show the thickness of the retinal ganglion cell layer and retinal nerve fiber layer increased by 30% to 100% in some eyes treated with GS010, and the improvements are occurring bilaterally in some cases. ■

## ROBERT C. SERGOTT, MD

P: 215/928-3130

Dr. Sergott did not indicate any proprietary interest in the subject matter.

# Let Us Be Your *Eyes and Ears*



## **Introducing EyePod: Podcasts from *Ophthalmology Times***

This new audible resource from *Ophthalmology Times* engages with key opinion leaders in interviews about the latest innovations in the areas of surgery, clinical diagnosis, pharmaceutical advancements, research, and technology, plus practice management.

Hear the voices of ophthalmic innovation.  
**[OphthalmologyTimes.com/EyePod](http://OphthalmologyTimes.com/EyePod)**

# research scholar honoree program

Supported by unrestricted grants from **REGENERON**



## FISH in focus for fast eye infection diagnosis

Despite cost, advantages include sensitivity, improved outcomes

By **Nimesh A. Patel, MD**; Mentors **Harry Flynn, MD**, and **Darlene Miller, MD**;  
Special to Ophthalmology Times

**W**e studied a technology that has been used in sepsis and in hospital-based bacterial detection systems—fluorescence in situ hybridization (FISH).

The goal is to achieve faster diagnosis in eye infections.

FISH offers advantages of being fast, sensitive, and specific with multiple samples at once. A disadvantage can be the cost. However, FISH is improving patient outcomes in septicemia, resulting in a reduction in ICU mortality, decreased length of hospital stays, and reduced costs.

### METHODS

The study used vitreous samples from patients with endophthalmitis; cornea samples from patients with

### EDITOR'S NOTE

► Ophthalmology Times is pleased to recognize **Nimesh A. Patel, MD**, fellow, **Bascom Palmer Eye Institute, University of Miami Miller School of Medicine**, as the **third-place honoree of the second Ophthalmology Times Research Scholar Honoree Program**. Dr. Patel's abstract is featured here.

*The Ophthalmology Times Research Scholar Honoree Program is dedicated to the education of retina fellows and residents by providing a unique opportunity for fellows/residents to share notable research and challenging cases with their peers and mentors. The program is supported by unrestricted grants from Regeneron Pharmaceuticals and Carl Zeiss Meditec Inc.*

infectious keratitis; and a commercial molecular kit for DNA hybridization.

### RESULTS

We used a molecular technique, a hybridization, where we dropped DNA probes onto the samples. We heated them up for 20 minutes and then looked at the florescents under the microscope.

In a comparison in *Candida* endophthalmitis, we found that FISH was nearly two days faster. It also proved to be effective, with no false positives. We were able to identify *staphylococci* in 19 of 20 samples.

We identified *Staphylococcus aureus* in nine of 10 samples and we detected Coag-negative *staphylococci*

in 10 of 10 samples. In FISH *Candida* keratitis, we were able to detect *Candida albicans* from a patient with endophthalmitis and keratitis. The results of FISH *Pseudomonas* keratitis were effective. We were able to detect *Pseudomonas aeruginosa* from a patient with keratitis.

In a comparison to PCR post incubation, FISH took 20 minutes, compared to four to five hours for PCR. It also was not labor intensive and had a sensitivity >90%, compared to >99% for PCR. Both had a specificity of 100%.

### CONCLUSION

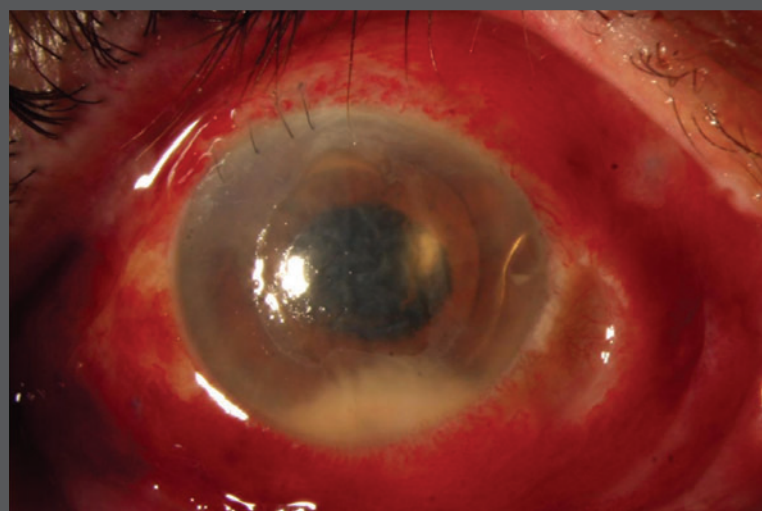
The novel use of FISH for the detection of pathogens from isolates in endophthalmitis and keratitis shows positive results. We found rapid and specific identification of bacteria and fungus one to two days faster than current culture methods with no false negatives, low labor intensity and an unknown cost utility. It could improve antimicrobial stewardship and allow for faster identification and treatment of endophthalmitis. Future studies will expand the project to include other ocular infections, testing from vitreous samples, and cost analysis. ■

### VIEW PRESENTATION ONLINE



#### VIDEO

See Dr. Patel's FISH presentation:  
Ophthalmology Times.com/  
patelnimesh



**Fluorescence in situ hybridization (FISH) may be able to achieve faster diagnosis in eye infections. It offers advantages of being fast, sensitive, and specific with multiple samples at once.**  
(Photos courtesy of Nimesh A. Patel, MD)

#### NIMESH A. PATEL, MD

E: [nimeshpatel300@gmail.com](mailto:nimeshpatel300@gmail.com)

Dr. Patel has no relevant financial interests to disclose.

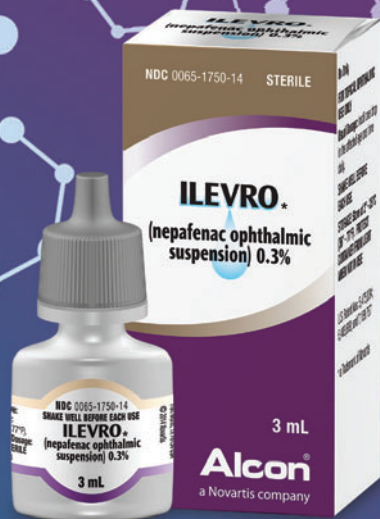**OT**

Look for more case study honorees in upcoming issues of **Ophthalmology Times**.

# ILEVRO®

(nepafenac ophthalmic suspension) 0.3%

Potency Precisely  
Where It's Needed



When treating pain and inflammation in your cataract surgery patients

## ACTIVATE SAVINGS FOR ILEVRO® SUSPENSION

For as little as \$15, eligible patients can access proven efficacy for post-cataract-surgery pain and inflammation.<sup>2,\*</sup>

- Ocular pain completely resolved in 84% to 86% of patients at day 14<sup>1-3,†,§</sup>
- Inflammation completely cleared in 61% to 65% of patients at day 14<sup>1-3,†,‡</sup>

ILEVRO® Suspension is the only prodrug NSAID formulated for once-daily post-op use.<sup>2,4-6</sup>

- ILEVRO® Suspension should be applied to the affected eye one-time-daily beginning 1 day prior to cataract surgery, continued on the day of surgery and through the first 2 weeks of the postoperative period. An additional drop should be administered 30 to 120 minutes prior to surgery.<sup>2</sup>
- Use of ILEVRO® Suspension more than 1 day prior to surgery or use beyond 14 days post surgery may increase patient risk and severity of corneal adverse events.<sup>2</sup>

DISCOVER SAVINGS AT [COPAY.NOVARTISPHARMA.COM](http://COPAY.NOVARTISPHARMA.COM)

### INDICATIONS AND USAGE

ILEVRO® (nepafenac ophthalmic suspension) 0.3% is a nonsteroidal, anti-inflammatory prodrug indicated for the treatment of pain and inflammation associated with cataract surgery.

### Dosage and Administration

One drop of ILEVRO® 0.3% should be applied to the affected eye one-time-daily beginning 1 day prior to cataract surgery, continued on the day of surgery and through the first 2 weeks of the postoperative period. An additional drop should be administered 30 to 120 minutes prior to surgery.

### IMPORTANT SAFETY INFORMATION

#### Contraindications

ILEVRO® 0.3% is contraindicated in patients with previously demonstrated hypersensitivity to any of the ingredients in the formula or to other nonsteroidal anti-inflammatory drugs (NSAIDs).

#### Warnings and Precautions

- **Increased Bleeding Time** – With some NSAIDs, including ILEVRO® 0.3%, there exists the potential for increased bleeding time. Ocularly applied NSAIDs may cause increased bleeding of ocular tissues (including hyphema) in conjunction with ocular surgery.
- **Delayed Healing** – Topical NSAIDs, including ILEVRO® 0.3%, may slow or delay healing. Concomitant use of topical NSAIDs and topical steroids may increase the potential for healing problems.

- **Corneal Effects** – Use of topical NSAIDs may result in keratitis. In some patients, continued use of topical NSAIDs may result in epithelial breakdown, corneal thinning, corneal erosion, corneal ulceration, or corneal perforation. These events may be sight threatening. Patients with evidence of corneal epithelial breakdown should immediately discontinue use of topical NSAIDs, including ILEVRO® 0.3%, and should be closely monitored for corneal health.

Patients with complicated ocular surgeries, corneal denervation, corneal epithelial defects, diabetes mellitus, ocular surface diseases (e.g., dry eye syndrome), rheumatoid arthritis, or repeat ocular surgeries within a short period of time may be at increased risk for corneal adverse events, which may become sight threatening. Topical NSAIDs should be used with caution in these patients.

Use more than 1 day prior to surgery or use beyond 14 days post surgery may increase patient risk and severity of corneal adverse events.

- **Contact Lens Wear** – ILEVRO® 0.3% should not be administered while using contact lenses.

#### Adverse Reactions

The most frequently reported ocular adverse reactions following cataract surgery occurring in approximately 5% to 10% of patients were capsular opacity, decreased visual acuity, foreign body sensation, increased intraocular pressure, and sticky sensation.

For additional information about ILEVRO® 0.3%, please refer to the Brief Summary of Prescribing Information on the adjacent page.

**Terms and Conditions:** Limitations apply. Eligible, commercially insured patients may pay as little as \$15 in out-of-pocket expenses for each 3-mL or 1.7-mL bottle of ILEVRO® 0.3%, with a maximum benefit per bottle of \$285. **This offer is not valid under Medicare, Medicaid, or any other federal or state program.** See additional terms and conditions at [www.copay.novartispharma.com](http://www.copay.novartispharma.com).

**Study Design:** Results from 2 randomized, multicenter, controlled, double-masked trials of adult patients undergoing cataract extraction. In Study 1, patients were randomized to receive either ILEVRO® Suspension (n=851), NEVANAC® Suspension (n=845), ILEVRO® Suspension vehicle (n=211), or NEVANAC® Suspension vehicle (n=213). In Study 2, patients were randomized to receive either ILEVRO® Suspension (n=540) or ILEVRO® Suspension vehicle (n=268).<sup>2,3</sup>

<sup>†</sup>61% to 65% with ILEVRO® Suspension versus 24% to 32% with vehicle;  $P < 0.05$ .

<sup>§</sup>84% to 86% with ILEVRO® Suspension versus 38% to 46% with vehicle;  $P < 0.05$ .

**References:** 1. Data on file. IMS Health. 2. Ilevro [package insert]. Fort Worth, TX: Alcon Laboratories, Inc; 2019. 3. Data on file. Novartis Pharmaceuticals Corporation; 2011. 4. BromSite (bromfenac ophthalmic solution) 0.075% [package insert]. Cranbury, NJ: Sun Pharma Global FZE; 2016. 5. Prolensa (bromfenac ophthalmic solution) 0.07% [prescribing information]. Bridgewater, NJ: Bausch & Lomb; 2016. 6. Nevanac (nepafenac ophthalmic suspension) 0.1% [package insert]. Fort Worth, TX: Alcon Laboratories Inc; 2017.

 NOVARTIS



**ILEVRO\* (nepafenac ophthalmic suspension) 0.3%, topical ophthalmic**  
**Initial U.S. Approval: 2005**

**BRIEF SUMMARY: Please see package insert for full prescribing information.**

#### **1 INDICATIONS AND USAGE**

ILEVRO\* 0.3% is indicated for the treatment of pain and inflammation associated with cataract surgery.

#### **4 CONTRAINDICATIONS**

ILEVRO\* 0.3% is contraindicated in patients with previously demonstrated hypersensitivity to any of the ingredients in the formula or to other nonsteroidal anti-inflammatory drugs (NSAIDs).

#### **5 WARNINGS AND PRECAUTIONS**

##### **5.1 Increased Bleeding Time**

With some NSAIDs including ILEVRO\* 0.3%, there exists the potential for increased bleeding time due to interference with thrombocyte aggregation. There have been reports that ocularly applied nonsteroidal anti-inflammatory drugs may cause increased bleeding of ocular tissues (including hyphema) in conjunction with ocular surgery.

It is recommended that ILEVRO\* 0.3% be used with caution in patients with known bleeding tendencies or who are receiving other medications which may prolong bleeding time.

##### **5.2 Delayed Healing**

Topical NSAIDs including ILEVRO\* 0.3%, may slow or delay healing. Topical corticosteroids are also known to slow or delay healing. Concomitant use of topical NSAIDs and topical steroids may increase the potential for healing problems.

##### **5.3 Corneal Effects**

Use of topical NSAIDs may result in keratitis. In some susceptible patients, continued use of topical NSAIDs may result in epithelial breakdown, corneal thinning, corneal erosion, corneal ulceration, or corneal perforation. These events may be sight threatening. Patients with evidence of corneal epithelial breakdown should immediately discontinue use of topical NSAIDs including ILEVRO\* 0.3% and should be closely monitored for corneal health.

Postmarketing experience with topical NSAIDs suggests that patients with complicated ocular surgeries, corneal denervation, corneal epithelial defects, diabetes mellitus, ocular surface diseases (e.g., dry eye syndrome), rheumatoid arthritis, or repeat ocular surgeries within a short period of time may be at increased risk for corneal adverse events, which may become sight threatening. Topical NSAIDs should be used with caution in these patients.

Postmarketing experience with topical NSAIDs also suggests that use more than 1 day prior to surgery or use beyond 14 days post-surgery may increase patient risk and severity of corneal adverse events.

##### **5.4 Contact Lens Wear**

ILEVRO\* 0.3% should not be administered while using contact lenses.

#### **6 ADVERSE REACTIONS**

Because clinical studies are conducted under widely varying conditions, adverse reaction rates observed in the clinical studies of a drug cannot be directly compared to the rates in the clinical studies of another drug and may not reflect the rates observed in practice.

##### **6.1 Serious and Otherwise Important Adverse Reactions**

The following adverse reactions are discussed in greater detail in other sections of labeling.

- Increased Bleeding Time [see *Warnings and Precautions (5.1)*]
- Delayed Healing [see *Warnings and Precautions (5.2)*]
- Corneal Effects [see *Warnings and Precautions (5.3)*]

#### **6.2 Ocular Adverse Reactions**

The most frequently reported ocular adverse reactions following cataract surgery were capsular opacity, decreased visual acuity, foreign body sensation, increased intraocular pressure (IOP), and sticky sensation. These reactions occurred in approximately 5% to 10% of patients.

Other ocular adverse reactions occurring at an incidence of approximately 1% to 5% included conjunctival edema, corneal edema, dry eye, lid margin crusting, ocular discomfort, ocular hyperemia, ocular pain, ocular pruritus, photophobia, tearing, and vitreous detachment.

Some of these reactions may be the consequence of the cataract surgical procedure.

#### **6.3 Non-Ocular Adverse Reactions**

Non-ocular adverse reactions reported at an incidence of 1% to 4% included headache, hypertension, nausea/vomiting, and sinusitis.

#### **8 USE IN SPECIFIC POPULATIONS**

##### **8.1 Pregnancy**

##### **Teratogenic Effects.**

**Pregnancy Category C:** Reproduction studies performed with nepafenac in rabbits and rats at oral doses up to 10 mg/kg/day have revealed no evidence of teratogenicity due to nepafenac, despite the induction of maternal toxicity. At this dose, the animal plasma exposure to nepafenac and amfenac was approximately 70 and 630 times human plasma exposure at the recommended human topical ophthalmic dose for rats and 20 and 180 times human plasma exposure for rabbits, respectively. In rats, maternally toxic doses greater than or equal to 10 mg/kg were associated with dystocia, increased postimplantation loss, reduced fetal weights and growth, and reduced fetal survival.

Nepafenac has been shown to cross the placental barrier in rats. There are no adequate and well-controlled studies in pregnant women. Because animal reproduction studies are not always predictive of human response, ILEVRO\* 0.3% should be used during pregnancy only if the potential benefit justifies the potential risk to the fetus.

##### **Non-teratogenic Effects**

Because of the known effects of prostaglandin biosynthesis inhibiting drugs on the fetal cardiovascular system (closure of the ductus arteriosus), the use of ILEVRO\* 0.3% during late pregnancy should be avoided.

##### **8.3 Nursing Mothers**

Nepafenac is excreted in the milk of lactating rats. It is not known whether this drug is excreted in human milk. Because many drugs are excreted in human milk, caution should be exercised when ILEVRO\* 0.3% is administered to a nursing woman.

##### **8.4 Pediatric Use**

The safety and effectiveness of ILEVRO\* 0.3% in pediatric patients below the age of 10 years have not been established.

##### **8.5 Geriatric Use**

No overall differences in safety and effectiveness have been observed between elderly and younger patients.

#### **ALCON®**

a Novartis Company

Distributed by:

Alcon Laboratories, Inc.  
Fort Worth, Texas 76134 USA

©2014, 2019 Novartis

\*a trademark of Novartis

T2019-21

# Study links long-term statin use with lower POAG risk

Patients who used statins for five years or more had reduced chance of glaucoma

By Lynda Charters

A team of researchers have conducted a study bringing the connection between statin use and the risk of primary open-angle glaucoma (POAG) into sharper focus. Investigators from Brigham and Women's Hospital have found that using statins for five or more years is linked to lower risk for POAG.

Jae Hee Kang, ScD, assistant professor of medicine in the Channing Division of Network Medicine at Brigham and Women's Hospital, Boston, was lead author of the study.

In vitro studies conducted in the 2000s indicated that statins may have the ability to decrease IOP and provide protection for the retinal ganglion cells against damage from glaucoma, according to the authors of a newly published study by Kang et al.<sup>1</sup>

"Our study suggests possible protective associations beyond cardiovascular conditions for long-term statin use," Dr. Kang said. "Statins may also strengthen neuroprotective mechanisms that prevent degeneration of cells in the optic nerve."

'Our study suggests possible protective associations beyond cardiovascular conditions for long-term statin use. Statins may also strengthen neuroprotective mechanisms.' — Jae Hee Kang, ScD

The association between statin use and POAG had been investigated previously, but the results were inconclusive and contradictory.

"Our primary a priori hypothesis was that longer duration of statin use is associated with a lower risk of POAG, and our secondary hypothesis was that higher cholesterol levels are associated with a higher risk of POAG," Dr. Kang and her team reported.

Dr. Kang and her team tracked 136,782 healthy patients (113,702 women, 23,080 men) who were 40 years of age and older who did not have glaucoma. The patients were drawn from the Nurses' Health Study (NHS) (patients followed from 2000 to 2014, Nurses' Health Study 2 (NHS2) (patients followed from 1999-2015), and the Health Professionals Follow-up Study (HPFS) (patients followed from 2000 to 2014).

A review of medical records confirmed the incident cases of POAG.

Data regarding development of glaucoma, assessment of high cholesterol, total serum cholesterol, statin use, and other cholesterol-lowering drugs had been collected biennially from patients. Main outcomes measures were the multivariable adjusted relative risks (RR) and 95% confidence intervals (CIs).

## STUDY FINDINGS

A total of 886 confirmed cases of incident POAG were identified (522 women in the NHS, 208 men in the HPFS, and 156 women in the NHS2; mean patient age, 68.5 years) during 1,485,498 person-years of follow-up, authors said.

"Longer statin use was not associated with known risk factors for glaucoma such as African American race/ethnicity or having a family history of glaucoma," the investigators noted.

Importantly, they found that every 20 mg/dL increase in the total serum cholesterol value was associated with a 7% increase in the risk of development of POAG (RR, 1.07; CI, 1.02-1.11). This finding reached significance ( $p = 0.004$ ).

They also reported that any self-reported history of elevated cholesterol levels was associated with a higher risk of development of POAG (RR, 1.17; CI, 1.00-1.37), and that a history of any use of statins was associated with a lower risk of development of

POAG (RR, 0.85 CI; 0.73-0.99). An important finding involved the longer use of statin, i.e., patients who used statins for 5 or more years had a 21% lower risk of development of POAG compared with patients who had never used statins (RR, 0.79; CI, 0.65-0.97).

"The inverse association between use of statins for 5 years or longer and risk of POAG was stronger among those who were 65 years or older (RR, 0.70; CI, 0.56-0.87) than among those younger than 65 years (RR, 1.05, CI, 0.68-1.63)," the investigators said.

This drug class may lower the risk of POAG development by IOP-lowering and neuroprotective mechanisms.

"Statins affect the activities of myosin II adenosine triphosphatase and p kinase in the trabecular network

that increase nitric oxide production and aqueous outflow facility, which may lead to some IOP lowering," investigators explained. "Also, greater production of nitric oxide would increase the blood flow to the optic nerve."

Additional neuroprotective effects that protect the retinal ganglion cells include anti-excitotoxic, anti-apoptotic, and anti-inflammatory effects.

"Among adults aged 40 years and older, higher serum cholesterol levels were associated with higher risk of POAG," the investigators concluded. "Five or more years of statin use compared with never use of statins was associated with a lower risk of POAG." ■

## REFERENCE

1. Jae H. Kang, Tahani Boumenna, Joshua D. Stein, Anthony Khawaja, Bernard A. Rosner, Janey L. Wiggs, Louis R. Pasquale. Association of statin use and high serum cholesterol levels with risk of primary open-angle glaucoma. *JAMA Ophthalmology*, 2019.

## JAE HEE KANG, SCD

E: nhjkh@channing.harvard.edu

Co-authors reported receiving personal fees from Allergan, Bausch + Lomb, Eyeovia, Grafton Optical, Novartis, Santen, and Thea.

## TAKE-HOME

► Statin use for an extended period may lead to a reduced risk of primary open-angle glaucoma.

# marketplace

For Products & Services and Recruitment advertising information, contact:  
**Joanna Shippoli** at 800-225-4569, ext 2615 • Fax 440-756-5271 • Email: [jshippoli@mmhgroup.com](mailto:jshippoli@mmhgroup.com)

## PRODUCTS & SERVICES

### BILLING SERVICES

Exclusive Ophthalmology Billers  
 Excellent Ophthalmology Billers  
 Expert Ophthalmology Billers  
**TRIPLE E = EVERYTHING GETS PAID**



**100% ONSHORE**  
 Ophthalmology/Optometry Billing  
**WE DO NOT OUTSOURCE OVERSEAS**

**P.M. Medical Billing is the largest, oldest and most experienced 100% onshore medical ophthalmology billing service in the United States. By ensuring our clients receive the maximum reimbursements for claims, we enable you to focus on expanding, buying the best equipment, spending more time with individual patients, and making the money that you deserve. Our ultimate goal has been and always will be to maximize our clients' revenue.**

#### P.M. Medical Billing Provides:

- Integration Into Your Current Practice Management & EMR
- A Dedicated Account Manager (Not A Call Center)
- Certified Ophthalmic Coders, Billers & Techs
- Experts In Forensic Billing & A/R Clean Up
- A Full In House Credentialing Department
- Low Cost Practice Management Software
- End To End Medical Billing & Follow Up
- Best Collection Rates In The Industry
- Full Service Patient Billing
- 100% HIPAA Compliance
- Fee Schedule Analysis

#### Practice Management Systems We Work With:

Nextech • NexGen • Imedicware  
 MD Office • Medisoft • Advanced MD  
 Azalea • Cerner • OfficeMate  
 Revolution • Management Plus • QRS  
 Medware • Dr. Chrono • Centricity  
 Intergy • Echo • Care Cloud • TCMS  
 Epic • Eclinical • Allscripts • ADS  
 and many more...

**CALL TODAY**  
**For A Free**  
**No Obligation**  
**Practice, Billing**  
**& A/R Analysis**

Email: [info@pmbiller.com](mailto:info@pmbiller.com)  
 Web: [www.pmbiller.com](http://www.pmbiller.com)

24 hours: 516-830-1500

**1-888-PM-BILLING**  
**(1-888-762-4554)**



Focused Medical Billing is a full service medical billing firm servicing all specialties of Ophthalmology. With our firm our focus is to maximize our client's revenue and dramatically decrease denials by utilizing 30 years of Ophthalmology billing/coding experience and expertise. Our firm provides accurate clean claim submissions on first submissions with relentless A/R follow up to obtain a 98% collection rate that so many of our clients enjoy.

#### Services Include:

- Expert Coders: Billing to Primary, Secondary & Tertiary insurance companies
- A/R Clean Up and analysis
- Patient Billing
- Posting of all Explanation of benefits
- Credentialing & Re-Credentialing
- Eligibility
- Fee Schedule Analysis
- Monthly Reports
- No long term commitment or contract required
- 100% HIPPA Compliant
- Stellar letters of reference

Call us today for your free, no obligation consultation

Ph: 855-EYE-BILL ext. 802  
 Email: [amay@focusedmedicalbilling.com](mailto:amay@focusedmedicalbilling.com)  
 Web: [www.focusedmedicalbilling.com](http://www.focusedmedicalbilling.com)

*"You're focused on your patients, we're focused on you"*



Reach your target audience.  
**Our audience.**

Ophthalmologists and allied eye care professionals.  
 Contact me today to place your ad.

**Joanna Shippoli**  
 Account Manager  
 440-891-2615  
[jshippoli@mmhgroup.com](mailto:jshippoli@mmhgroup.com)

**Ophthalmology Times**

PRODUCTS & SERVICES

BILLING SERVICES

**ECBC**  
EYE CARE BILLING CONSULTANTS

SEE YOUR PROFITS MORE CLEARLY


Ophthalmology & Optometry Billing Only  
New York City based  
25 years of experience

eyecarebillingconsultants.com  
contact@eyecarebillingconsultants.com  
(646) 828-8889

Reach your target audience.

**Our audience.**

Ophthalmologists and allied eye care professionals.  
Contact me to place your ad.



**Joanna Shippoli**

Account Manager

440-891-2615

[jshippoli@mmhgroup.com](mailto:jshippoli@mmhgroup.com)

**Ophthalmology Times**



Narrow your candidate search **to the best.**

Place a recruitment ad in *Ophthalmology Times* — in print or online.

**Joanna Shippoli**

Account Manager | 440-891-2615

[jshippoli@mmhgroup.com](mailto:jshippoli@mmhgroup.com)

**Ophthalmology Times**

# Exploring dry eye symptoms that worsen during night

Poor eyelid performance while sleeping a common contributing factor

By **Laura M. Periman, MD**; Special to Ophthalmology Times

**W**e educate our patients on the role of sleep as a facilitator of overall good health. But what happens when our diligent sleepers wake up with dry eye symptoms that are decidedly worse, not better? The strange phenomena of my patients getting more and better sleep—and still waking up with peak severity dry eye symptoms—led me to investigate the cause of, and potential remedies for, symptomatic dry eye that worsens overnight.

According to recent research published by Korb et al. in 2017, poor eyelid performance while sleeping—and subsequently, the nocturnal evaporative stress (NES) that follows—is prevalent in patients suffering from refractory dry eye. They identified that poor lid performance correlates relatively neatly with moderate-to-severe symptoms.<sup>1</sup>

This research is significant because NES is a frequently overlooked and undermanaged component of dry eye care.

By taking a more proactive approach to identifying and managing this nuanced set of aggravators, we can help soften our patients' symptoms and boost their quality of life.

First, we should recognize that the severity of nocturnal evaporative stress is influenced by both external and internal factors as well as meibomian gland dysfunction (MGD).

External factors, such as those studied by Korb et al., are essentially biomechanical failures—for instance, poor lid performance, sleeping position preference or the presence of floppy eyelid syndrome (which has been shown to negatively impact the tear film's functionality).<sup>2</sup>

Internal factors may include medications, allergic responses to dust mites, or direct contact with turbulent vent and fan air, all of which can induce desiccating stress that damages the eye's protective layers, aqueous or lipid.

Dry-eye practitioners are good at investigating external factors. Careful examination for evidence of poor nocturnal lid performance is a good place

to start, as diagnostic testing and remedial options are both straightforward and effective.

We can improve our considerations and assessments for a wider range of internal factors with improved knowledge of common ocular surface drying medications.

## TESTING THE LIDS

To test my patients' lid performance, I adopted the Korb-Blackie lid leak test, a way to evaluate dry eye symptom prevalence and severity with respect to lid closure.<sup>3</sup>

The test itself is simple: In a darkened room, place a muscle light or transilluminator gently at the upper tarsus of the closed eye, and direct the light toward the interpalpebral fissure. If light escapes between the eyelids, it is a positive test. More light leakage indicates a more significant nocturnal lid seal insufficiency which is associated with more exposure/desiccating stress and greater symptom severity.<sup>1</sup>

This test is part of my standard dry eye diagnostic workup and takes 15 seconds to perform. We record this in the EMR as "Lid Seal Insufficiency"—negative, mild, moderate, or severe—based on the amount of light leaking in between the closed eyelids.

I then perform a "snap test": pulling gently on the patient's upper and

lower lids to assess elasticity, with slow return to normal position indicating a lack of elasticity and lid performance.

Lift the upper lids to look for excess laxity, papillary reaction of the superior palpebral conjunctiva. These two findings, in addition to temporal upper eyelash ptosis, suggests floppy eyelid syndrome and a sleep study for obstructive sleep apnea is ordered. If light escapes, the lids are not adequately protecting the ocular surface.

I've observed in cases of asymmetric lid seal insufficiency that the meibomian gland drop is often more pronounced on the more severe lid seal insufficiency side.

Once poor nocturnal lid protection is identified, I first instruct them to direct fans and vents away

from the head. I also tell them to avoid dust-mite allergens and to purchase a high-quality sleep mask.

This approach to identifying and managing poor nocturnal lid protection is particularly helpful for patients with micro-exposures, since reduction of ongoing desiccating stress may help us manage MGD.

Research from Jester et al. showed that inducing desiccating stress in mice created an altered protein-to-lipid ratio in the meibomian gland, inducing MGD in this in vivo mouse model.<sup>4</sup> Specifically, the meibomian glands upregulated cell turnover in response to desiccating stress, inducing faster meibum production yet with an abnormal protein-to-lipid ratio.

As with any animal study, it is important to realize the limitations of early research and base clinical decisions primarily on human-based evidence. We understand that MGD is a complex, multifactorial condition that influences the broader dry eye "vicious circles."

## CONCLUSION

By treating nocturnal evaporative stress in our MGD patients, we have much to gain with very little to lose. We are often forced to minimize our patient consultation time and see as many patients as possible. It is tempting to run new dry eye patients through a minimalist protocol or script that covers the basics: medication, lifestyle, and other surface-level factors that provide important, but not comprehensive information.

Identifying nocturnal evaporative stress is worth the time spent. If we are going to recommend patients focus on good sleep hygiene and habits, we should also ensure that their eyes are also getting full rest from drying exposures. ■

OT

For references, visit the online article at the link here: [bit.ly/2Lfvb5A](https://bit.ly/2Lfvb5A)



**LAURA M. PERIMAN, MD**

E: [lauraperiman@yahoo.com](mailto:lauraperiman@yahoo.com)

Dr. Periman is a speaker for Allergan, Lumenis, Novartis, Shire, Sun Pharmaceutical, and Takeda, and she serves as a consultant for Eyedetec, EyeVance, Science Based Health, TearLab, Visant, and Umay.

# 20/20 vision can get in the way of a masterpiece



“I’m worried if my vision is corrected it will ruin my art career!”

Artwork by Jon Carter

## *in case you missed it*

**Macular OCT assists preop cataract surgery evaluation** [PAGE 10](#)

**Setting glaucoma patients’ cataract surgery expectations** [PAGE 16](#)

**Facing challenge of corneal infection management** [PAGE 25](#)

**Exploring dry eye symptoms that worsen during night** [PAGE 36](#)



**(PODCAST) Here’s why you should add IPL therapy to your practice**

[OPHTHALMOLOGYTIMES.COM/EYEPOD](http://OPHTHALMOLOGYTIMES.COM/EYEPOD)

**Hey, chocolate chip cookie fans!**

[OPHTHALMOLOGYTIMES.COM/COOKIES](http://OPHTHALMOLOGYTIMES.COM/COOKIES)

## *next issue...*

**New horizons in IOL innovation**

## Advertiser Index

Advertiser	Page	Advertiser	Page	Advertiser	Page
<b>CLEARSIDE BIOMEDICAL</b> clearsidebio.com	<b>5</b>	<b>JOHNSON &amp; JOHNSON VISION</b> surgical.jnjvision.com/	<b>20–21, CV4</b>	<b>OCULAR THERAPEUTIX</b> ocutx.com 877-628-8998	<b>11-12</b>
<b>COLUMBIA UNIVERSITY MEDICAL CENTER</b> <b>EDWARD S. HARKNESS EYE INSTITUTE</b> columbiaeye.org/Precision2020	<b>13</b>	<b>MAINE SOCIETY OF EYE PHYSICIANS AND SURGEONS</b> maineeyemds.com 207/445-2260	<b>19</b>	<b>OMEROS CORP.</b> omeros.com 206/676-5000	<b>CV2–3</b>
<b>DOMPE PHARMACEUTICALS INC.</b>	<b>38, CV3</b>	<b>NOVARTIS OPHTHALMICS</b> pharma.us.novartis.com 888/669-6682	<b>15, 23–24, 31–32</b>	<b>SHIRE OPHTHALMIC</b> Xiidra-ECP.com 800/828-2088	<b>6-8</b>
<b>DUTCH OPHTHALMIC USA</b>	<b>27</b>				
<b>EYEVANCE PHARMACEUTICALS</b> eyevance.com 817/677 6120	<b>17</b>				

This index is provided as an additional service. The publisher does not assume any liability for errors or omissions.

## Brief Summary of Safety

Consult the full Prescribing Information for complete product information.

### INDICATIONS AND USAGE

OXERVATE™ (cenegermin-bkjb) ophthalmic solution 0.002% is indicated for the treatment of neurotrophic keratitis.

### DOSAGE AND ADMINISTRATION

Contact lenses should be removed before applying OXERVATE and may be reinserted 15 minutes after administration.

If a dose is missed, treatment should be continued as normal, at the next scheduled administration.

If more than one topical ophthalmic product is being used, administer the eye drops at least 15 minutes apart to avoid diluting products. Administer OXERVATE 15 minutes prior to using any eye ointment, gel or other viscous eye drops.

### Recommended Dosage and Dose Administration

Instill one drop of OXERVATE in the affected eye(s), 6 times a day at 2-hour intervals for eight weeks.

### ADVERSE REACTIONS

Clinical Studies Experience Because clinical studies are conducted under widely varying conditions, adverse reaction rates observed in the clinical studies of a drug cannot be directly compared to rates in the clinical studies of another drug and may not reflect the rates observed in practice.

In two clinical trials of patients with neurotrophic keratitis, a total of 101 patients received cenegermin-bkjb eye drops at 20 mcg/mL at a frequency of 6 times daily in the affected eye(s) for a duration of 8 weeks. The mean age of the population was 61 to 65 years of age (18 to 95). The majority of the treated patients were female (61%). The most common adverse reaction was eye pain following instillation which was reported in approximately 16% of patients. Other adverse reactions occurring in 1-10% of OXERVATE patients and more frequently than in the vehicle-treated patients included corneal deposits, foreign body sensation, ocular hyperemia, ocular inflammation and tearing.

### USE IN SPECIFIC POPULATIONS

#### Pregnancy

Risk Summary There are no data from the use of OXERVATE in pregnant women to inform any drug associated risks.

Administration of cenegermin-bkjb to pregnant rats or rabbits during the period of organogenesis did not produce adverse fetal effects at clinically relevant doses. In a pre- and postnatal development study, administration of cenegermin-bkjb to pregnant rats throughout gestation and lactation did not produce adverse effects in offspring at clinically relevant doses.

#### Animal Data

In embryofetal development studies, daily subcutaneous administration of cenegermin-bkjb to pregnant rats and rabbits throughout the period of organogenesis produced a slight increase in post-implantation loss at doses greater than or equal to 42 mcg/kg/day (267 times the MRHOD). A no observed adverse effect level (NOAEL) was not established for post-implantation loss in either species.

In rats, hydrocephaly and ureter anomalies were each observed in one fetus at 267 mcg/kg/day (1709 times the MRHOD). In rabbits, cardiovascular malformations, including ventricular and atrial septal defects, enlarged heart and aortic arch dilation were each observed in one fetus at 83 mcg/kg/day (534 times the MRHOD). No fetal malformations were observed in rats and rabbits at doses of 133 mcg/kg/day and 42 mcg/kg/day, respectively. In a pre- and postnatal development study, daily subcutaneous administration of cenegermin-bkjb to pregnant rats during the period of organogenesis and lactation did not affect parturition and was not associated with adverse toxicity in offspring at doses up to 267 mcg/kg/day. In parental rats and rabbits, an immunogenic response to cenegermin-bkjb was observed. Given that cenegermin-bkjb is a heterologous protein in animals, this response may not be relevant to humans.

#### Lactation

There are no data on the presence of OXERVATE in human milk, the effects on breastfed infant, or the effects on milk production. The developmental and health benefits of breastfeeding should be considered, along with the mother's clinical need for OXERVATE, and any potential adverse effects on the breastfed infant from OXERVATE.

#### Pediatric Use

The safety and effectiveness of OXERVATE have been established in the pediatric population. Use of OXERVATE in this population is supported by evidence from adequate and well-controlled trials of OXERVATE in adults with additional safety data in pediatric patients from 2 years of age and older [see *Clinical Studies (14)*].

#### Geriatric Use

Of the total number of subjects in clinical studies of OXERVATE, 43.5 % were 65 years old and over. No overall differences in safety or effectiveness were observed between elderly and younger adult patients.

### NONCLINICAL TOXICOLOGY

Carcinogenesis and Mutagenesis Animal studies have not been conducted to determine the carcinogenic and mutagenic potential of cenegermin-bkjb.

Impairment of fertility Daily subcutaneous administration of cenegermin-bkjb to male and female rats for at least 14 days prior to mating, and at least 18 days post-coitum had no effect on fertility parameters in male or female rats at doses up to 267 mcg/kg/day (1709 times the MRHOD). In general toxicology studies, subcutaneous and ocular administration of cenegermin-bkjb in females was associated with ovarian findings including persistent estrus, ovarian follicular cysts, atrophy/reduction of corpora lutea, and changes in ovarian weight at doses greater than or equal to 19 mcg/kg/day (119 times the MRHOD).



The first FDA-approved pharmacologic  
therapy indicated for the treatment  
of neurotrophic keratitis<sup>1,2</sup>

**oxervate**<sup>™</sup>   
(cenegermin-bkbj ophthalmic  
solution) 0.002% (20 mcg/mL)

Learn more at [Oxervate.com/HCP](https://Oxervate.com/HCP)

## Important Safety Information

### WARNINGS AND PRECAUTIONS

Patients should remove contact lenses before applying OXERVATE and wait 15 minutes after instillation of the dose before reinsertion.

### ADVERSE REACTIONS

The most common adverse reaction in clinical trials that occurred more frequently with OXERVATE was eye pain (16% of patients). Other adverse reactions included corneal deposits, foreign body sensation in the eye, ocular hyperemia, swelling of the eye, and increase in tears (1%-10% of patients).

**For additional safety information, see accompanying Brief Summary of Safety Information on the adjacent page and full Prescribing Information on [Oxervate.com/HCP](https://Oxervate.com/HCP).**



**References:** 1. OXERVATE (cenegermin-bkbj) full prescribing information. Dompé. May 2019. 2. FDA approves first drug for neurotrophic keratitis, a rare eye disease [FDA news release]. August 22, 2018.

© 2019 Dompé U.S. Inc. All rights reserved.  
US-OXE-1900008 06/19



# TECNIS<sup>®</sup> PERSONALIZED VISION

TECNIS<sup>®</sup>  
Symfony<sup>®</sup>  
Extended Range of Vision IOLs



TECNIS<sup>®</sup>  
Multifocal IOLs  
+3.25 D



Not an actual patient.

## Seamless clarity from near to far.<sup>1</sup>

Because his passion is on the line.

TECNIS<sup>®</sup> Personalized Vision refers to combining a TECNIS<sup>®</sup> Symfony<sup>®</sup> IOL in one eye and a TECNIS<sup>®</sup> Multifocal IOL in the fellow eye.

[Learn more at TecnisIOL.com](https://www.tecnisIOL.com)

### Indications and Important Safety Information Rx Only

#### TECNIS SYMFONY<sup>®</sup> EXTENDED RANGE OF VISION IOL

**INDICATIONS:** The TECNIS<sup>®</sup> Symfony<sup>®</sup> Extended Range of Vision IOL, Model ZXR00, is indicated for primary implantation for the visual correction of aphakia, in adult patients with less than 1 diopter of pre-existing corneal astigmatism, in whom a cataractous lens has been removed. The lens mitigates the effects of presbyopia by providing an extended depth of focus. Compared to an aspheric monofocal IOL, the lens provides improved intermediate and near visual acuity, while maintaining comparable distance visual acuity. The Model ZXR00 IOL is intended for capsular bag placement only. **WARNINGS:** Patients with any of the conditions described in the Directions for Use may not be suitable candidates for an intraocular lens because the lens may exacerbate an existing condition, may interfere with diagnosis or treatment of a condition, or may pose an unreasonable risk to the patient's eyesight. Lenses should not be placed in the ciliary sulcus. May cause a reduction in contrast sensitivity under certain conditions, compared to an aspheric monofocal IOL; fully inform the patient of this risk before implanting the lens. Special consideration should be made in patients with macular disease, amblyopia, corneal irregularities, or other ocular disease. Inform patients to exercise special caution when driving at night or in poor visibility conditions. Some visual effects may be expected due to the lens design, including: a perception of halos, glare, or starbursts around lights under nighttime conditions. These will be bothersome or very bothersome in some people, particularly in low-illumination conditions, and on rare occasions, may be significant enough that the patient may request removal of the IOL. **SERIOUS ADVERSE EVENTS:** The most frequently reported serious adverse events that occurred during the clinical trial of the TECNIS<sup>®</sup> Symfony<sup>®</sup> lens were cystoid macular edema (2 eyes, 0.7%) and surgical re-intervention (treatment injections for cystoid macular edema and endophthalmitis, 2 eyes, 0.7%). No lens-related adverse events occurred during the trial.

#### TECNIS<sup>®</sup> MULTIFOCAL FAMILY OF 1-PIECE IOLs

**INDICATIONS:** The TECNIS<sup>®</sup> Multifocal 1-Piece intraocular lenses are indicated for primary implantation for the visual correction of aphakia in adult patients with and without presbyopia in whom a cataractous lens has been removed by phacoemulsification and who desire near, intermediate, and distance vision with increased spectacle independence. The intraocular lenses are intended to be placed in the capsular bag. **WARNINGS:** Physicians considering lens implantation should weigh the potential risk/benefit ratio for any conditions described in the Directions for Use that could increase complications or impact patient outcomes. Multifocal IOL implants may be inadvisable in patients where central visual field reduction may not be tolerated, such as macular degeneration, retinal pigment epithelium changes, and glaucoma. The lens should not be placed in the ciliary sulcus. Inform patients about the possibility that a decrease in contrast sensitivity and an increase in visual disturbances may affect their ability to drive a car under certain environmental conditions, such as driving at night or in poor visibility conditions. **PRECAUTIONS:** Prior to surgery, inform prospective patients of the possible risks and benefits associated with the use of this device and provide a copy of the patient information brochure to the patient. Secondary glaucoma has been reported occasionally in patients with controlled glaucoma who received lens implants. **ADVERSE EVENTS:** The rates of surgical re-interventions, most of which were non-lens related, were statistically higher than the FDA grid rate for the ZLB00 (+3.25 D) lens model. The re-intervention rate was 3.3% for both the first and second eyes in the ZLB00 group.

**ATTENTION:** Reference the Directions for Use for a complete listing of Indications and Important Safety Information.

**REFERENCE: 1.** DOF2018CT4021. Johnson & Johnson Surgical Vision, Inc; 2018.  
TECNIS<sup>®</sup> and TECNIS<sup>®</sup> Symfony<sup>®</sup> are trademarks of Johnson & Johnson Surgical Vision, Inc.  
©Johnson & Johnson Surgical Vision, Inc. 2019 | TecnisIOL.com | PP2019MLT4138 | June 2019

See the Passion in  
Each Patient

*Johnson & Johnson* VISION